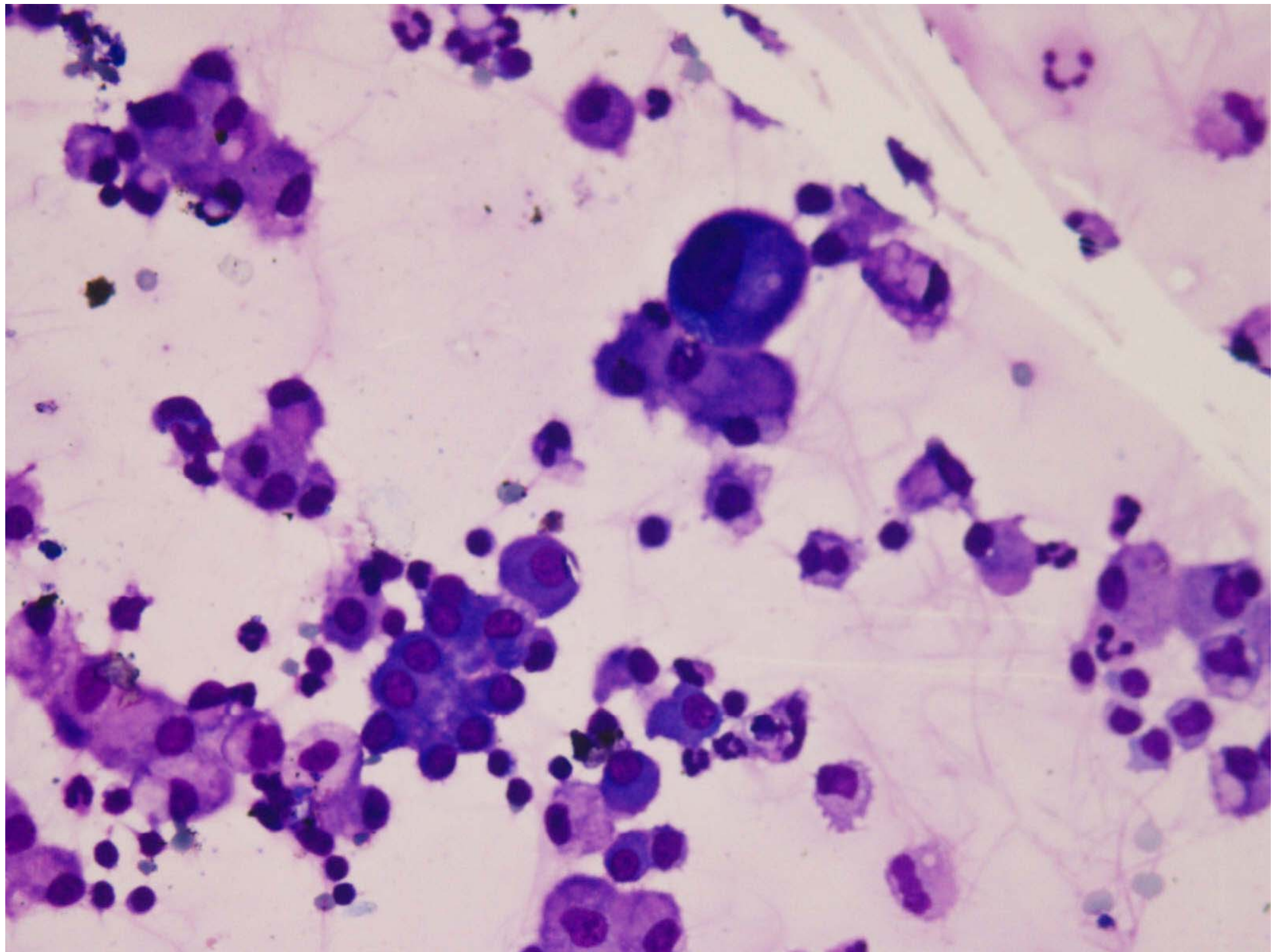
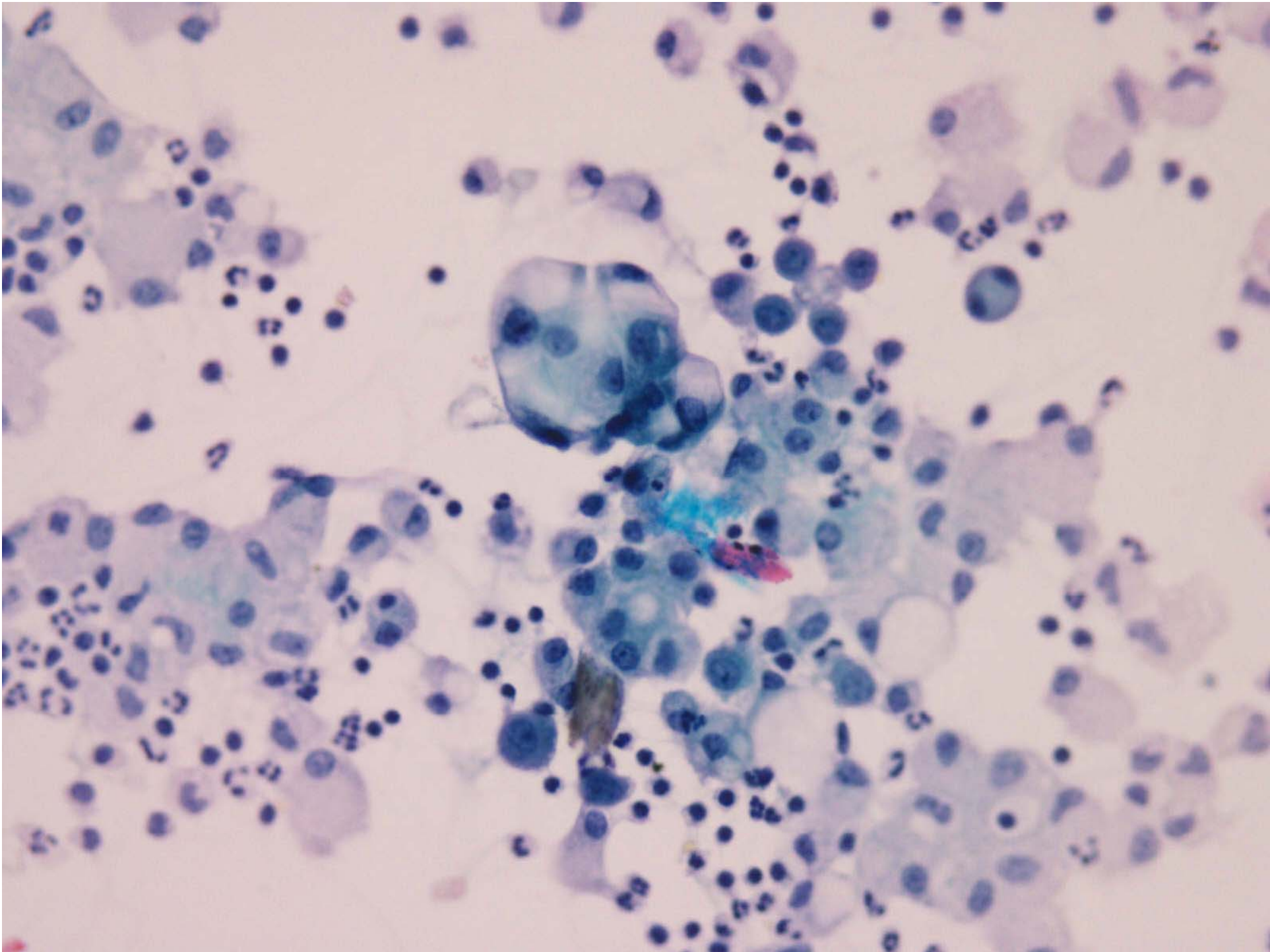


# CASE 1

- 65 M.
- History of right sided hemeparesis
- SOL Right parieto-occipital region
- CSF examination (2 Pics)



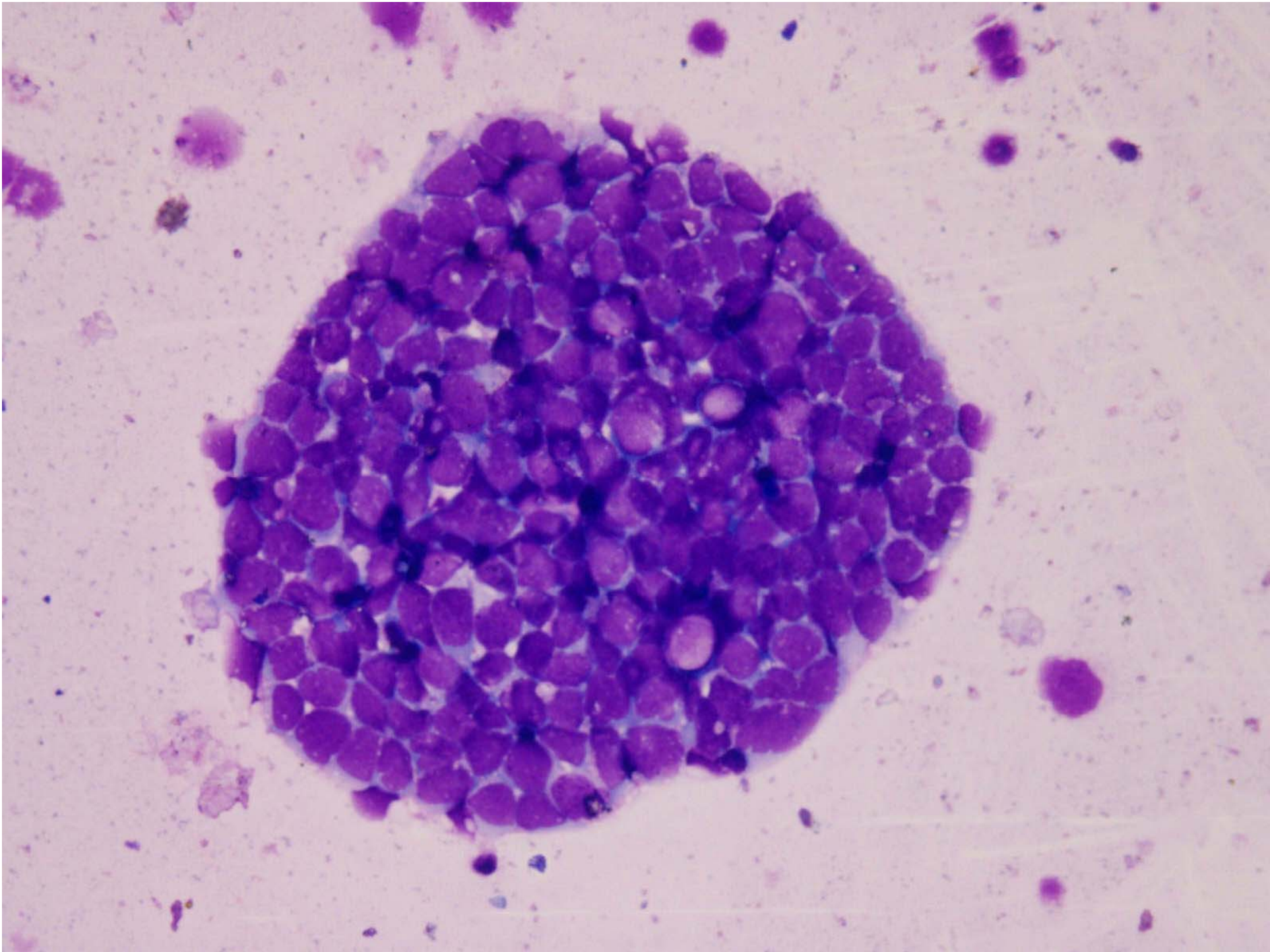


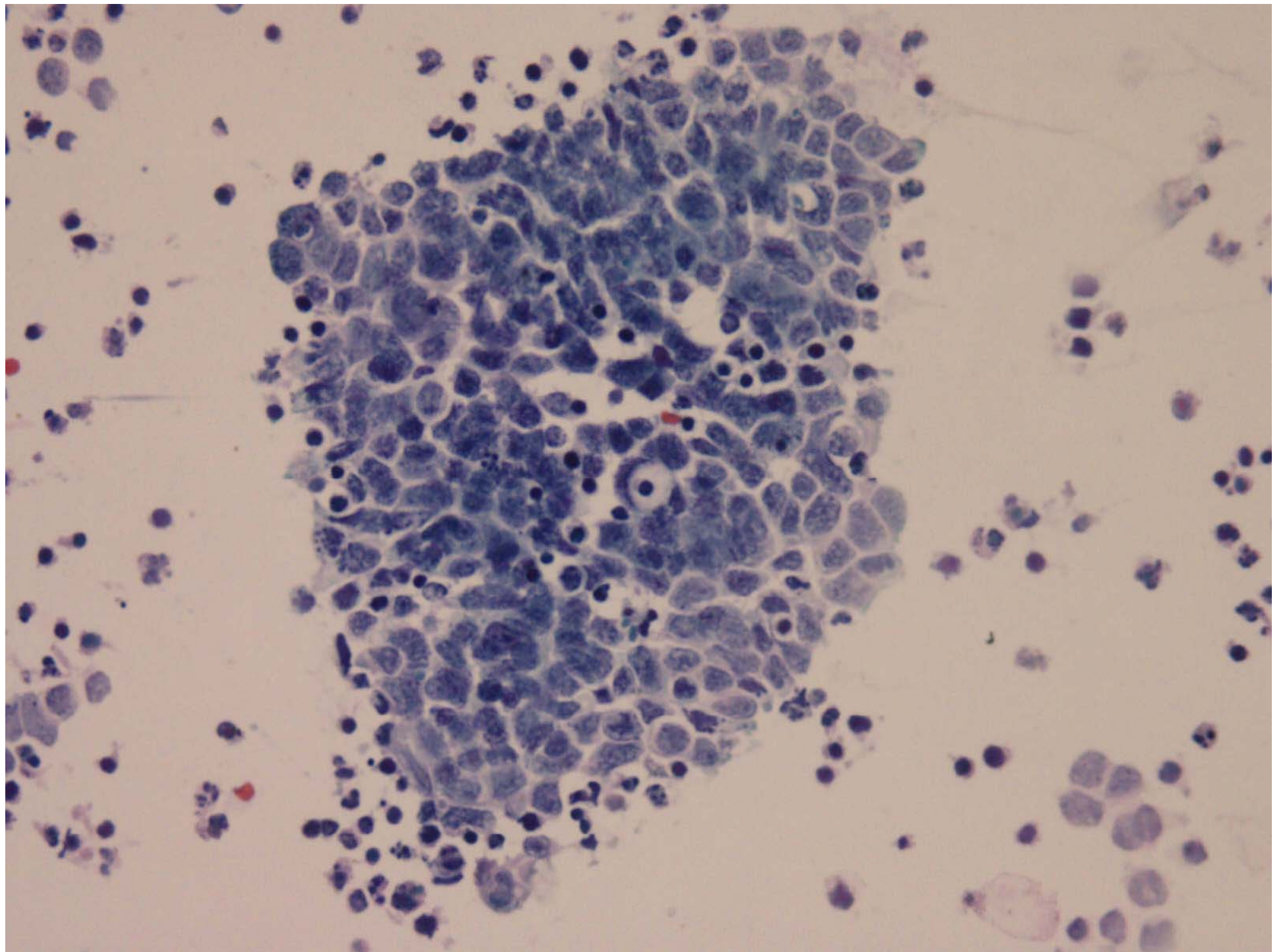
- What is your Diagnosis ?

## Case 2

- 4166/11 8 years Male
- Presented with ataxia CT shows a large tumor in the vermix
- Lethargy and focal seizure, raised intra cranial tension
- CSF for examination(2 pics)





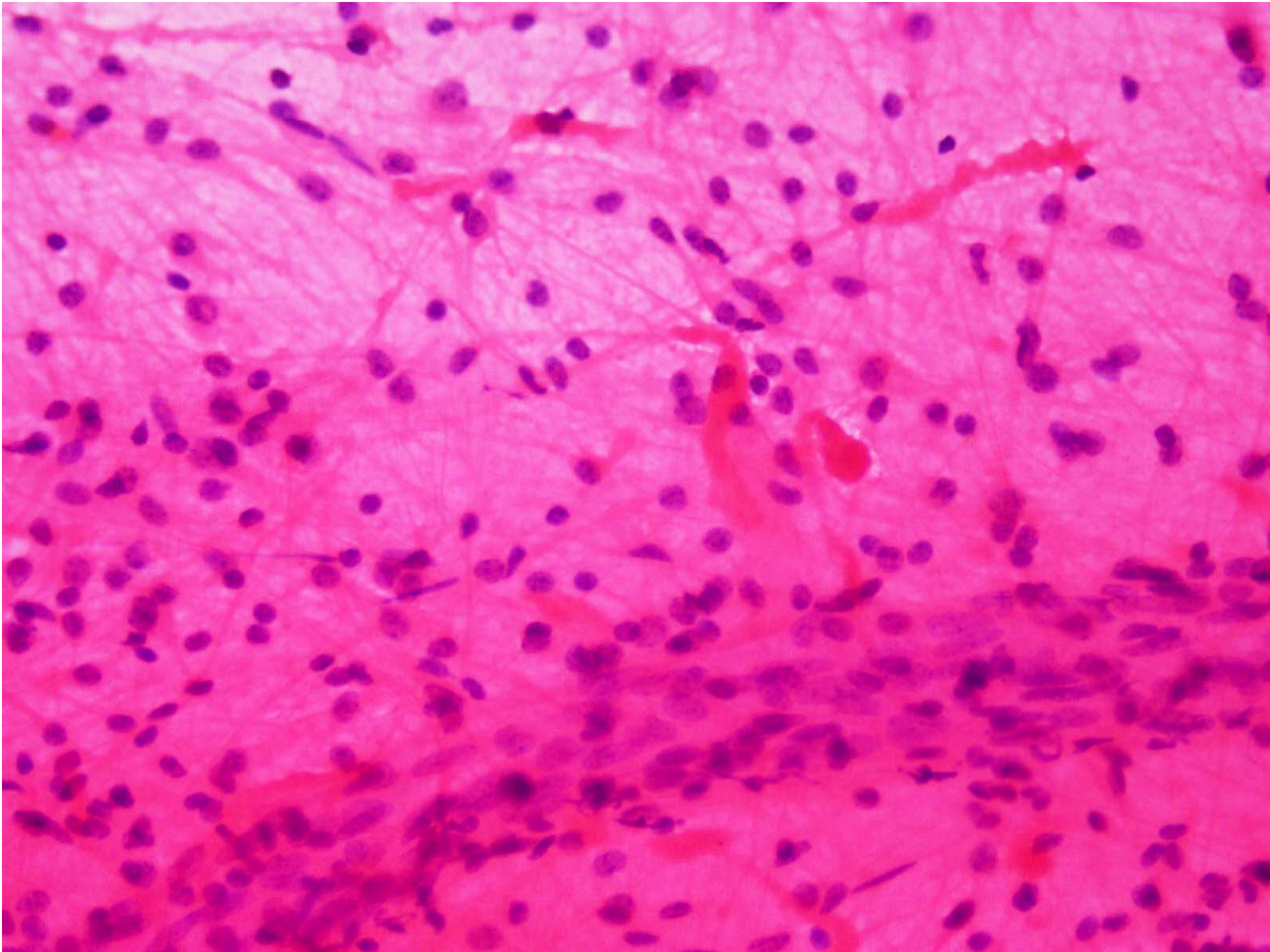


- What is your diagnosis?

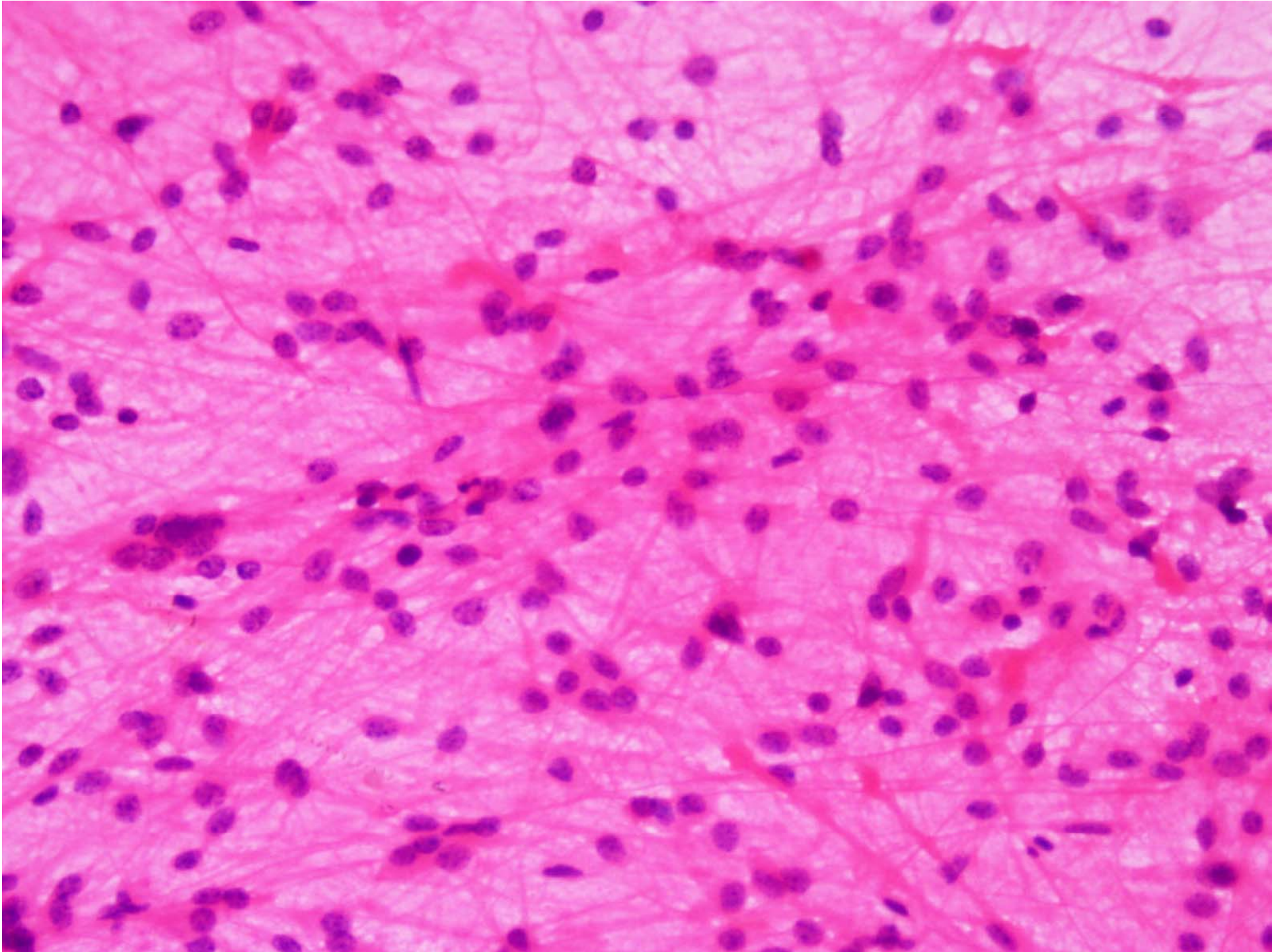


## Case 3

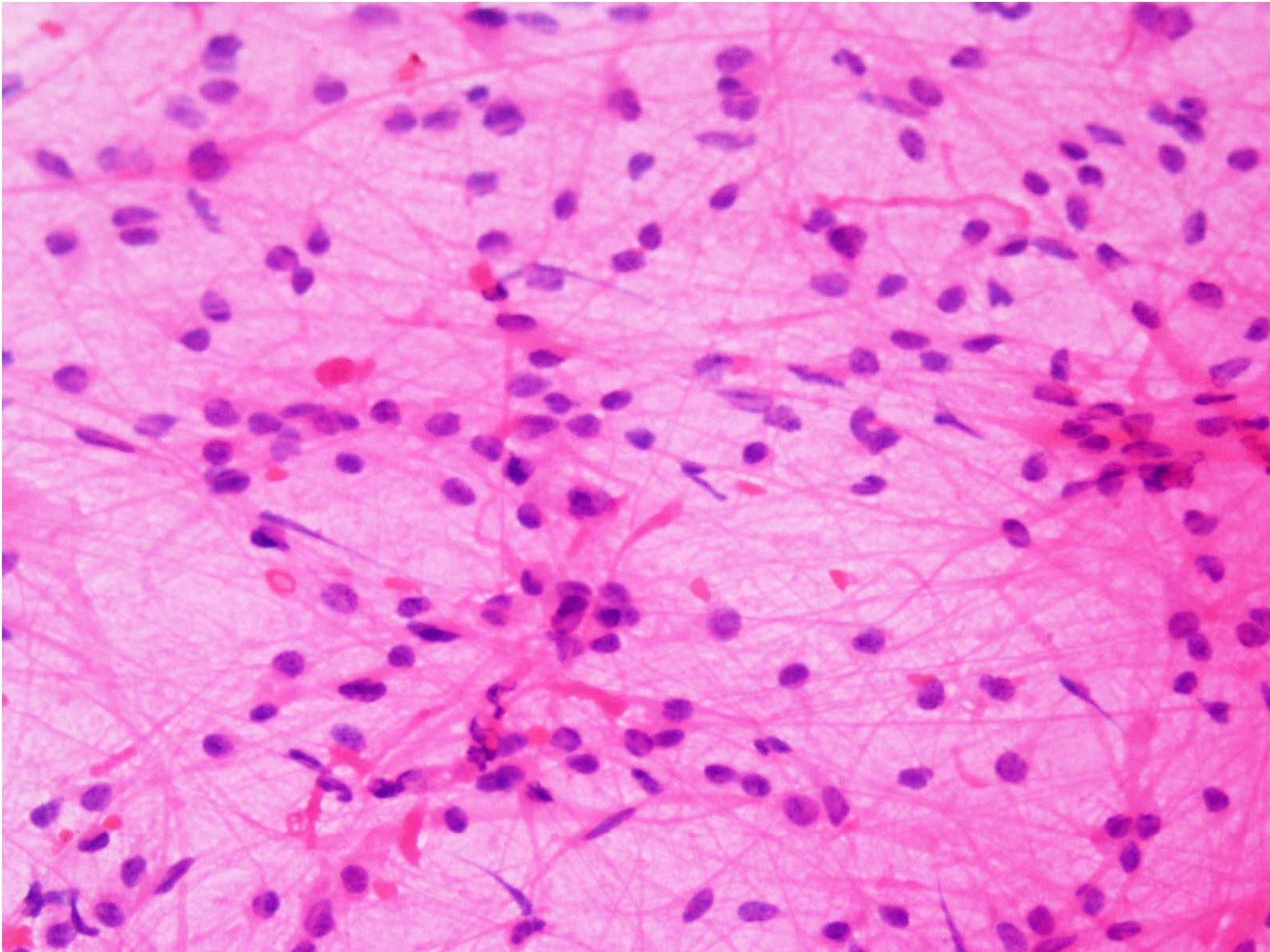
- 12 male years Male,
- Posterior fossa mass lesion
- MRI shows midline tumor in cerebellar vermis
- Stereotactic Crush smear









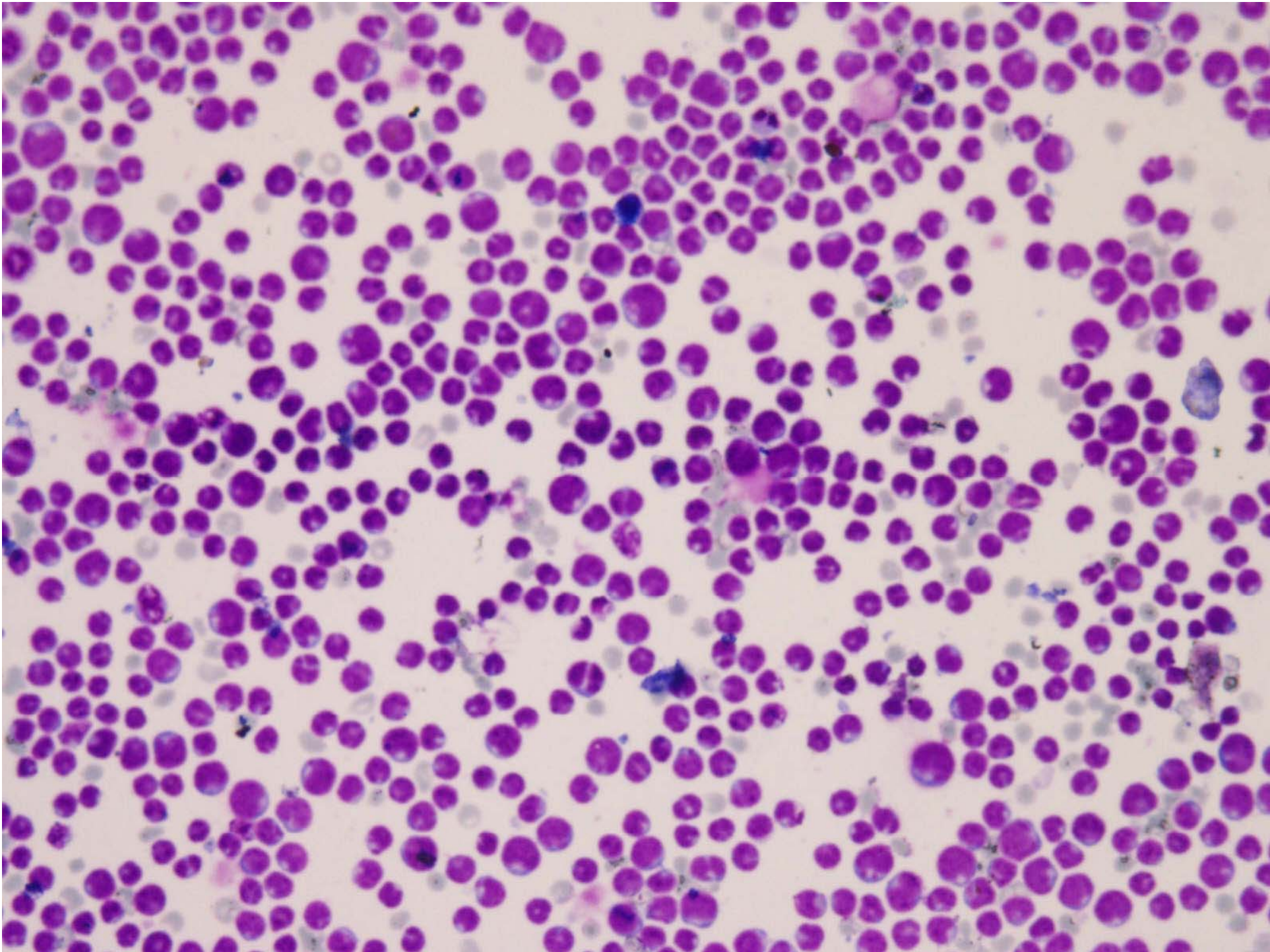




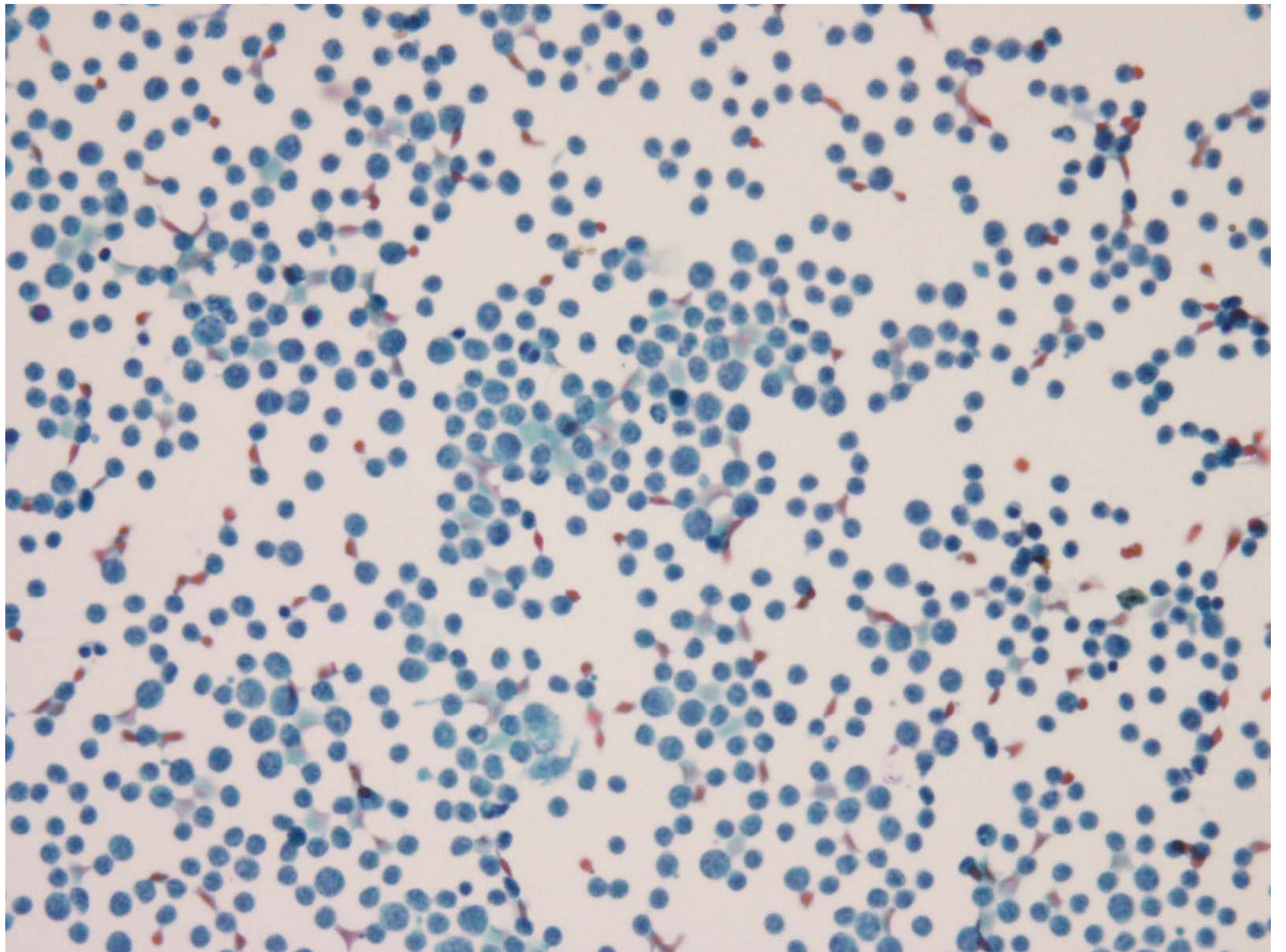
- What is your Diagnosis?

# Case 4

- 40 M,
- Fever, Headache, Seizure
- CSF Examination (2 Pics)









- What is your Diagnosis?