

BREAST - SLIDE SEMINAR

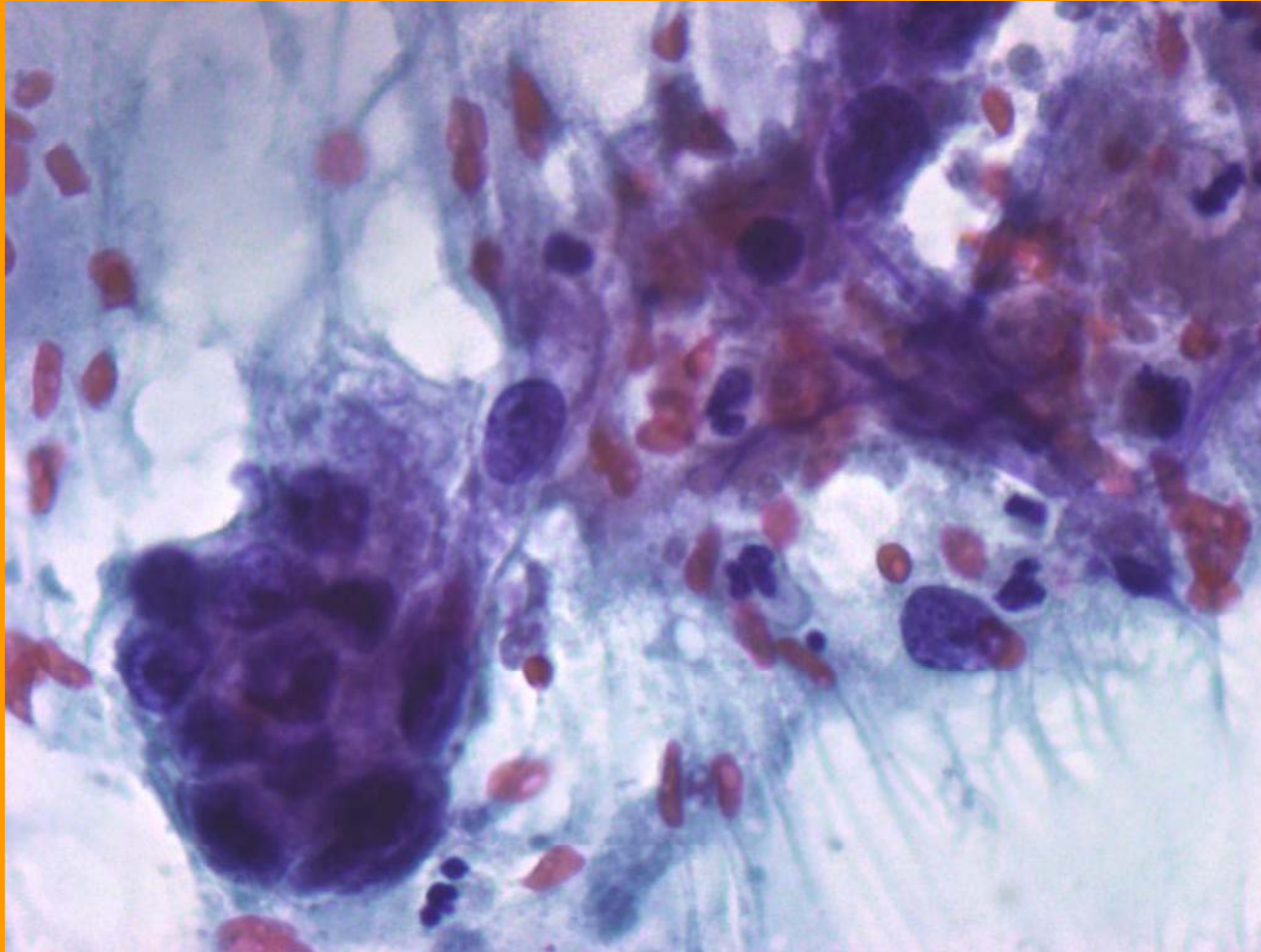
**37th European Congress of Cytology,
Croatia 2012**

**Hara Margari
Head, Cytopathology Department of
General-Maternity Hospital “Elena Venizelou”.**

Case report

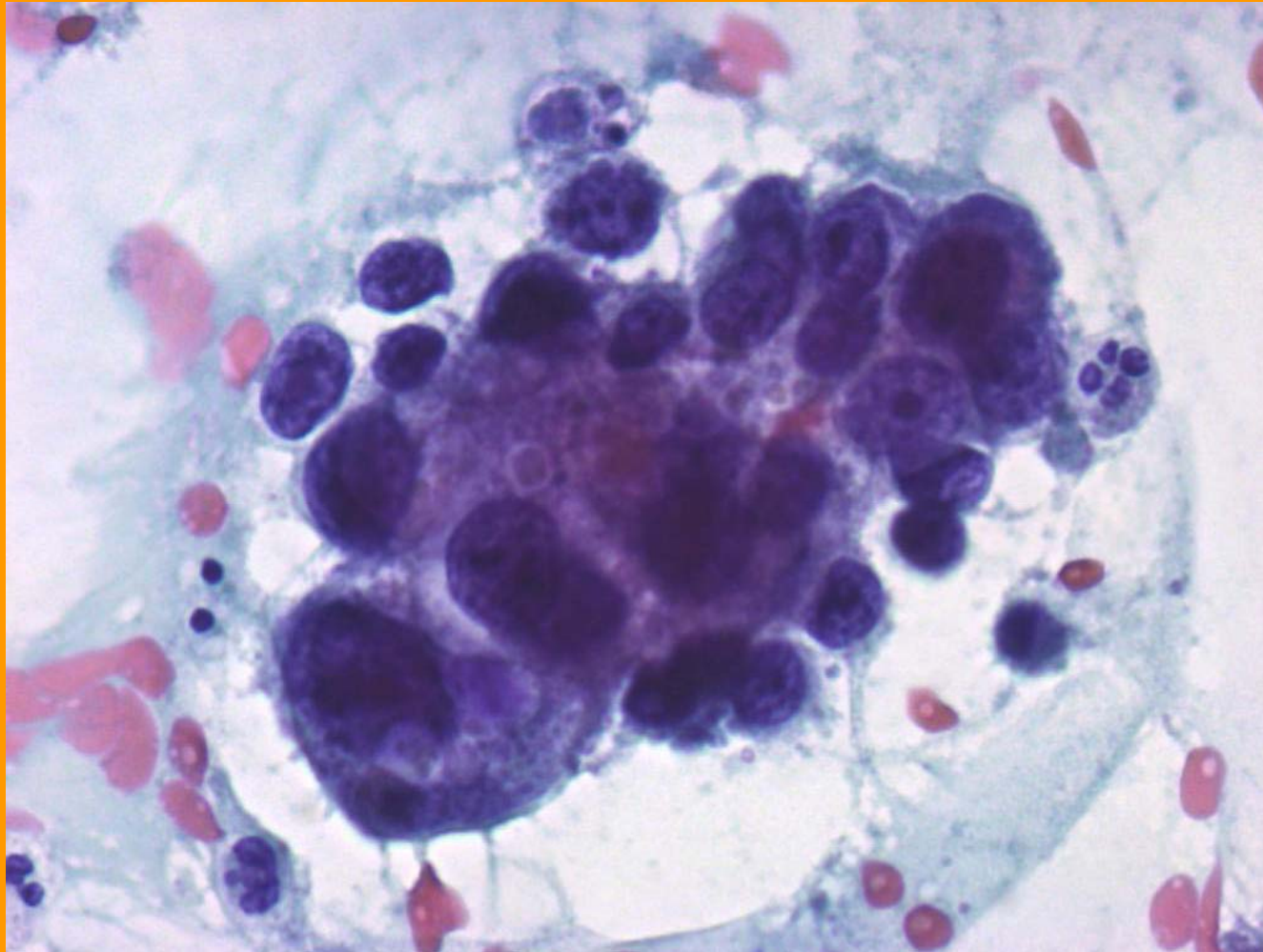
- A 30 year-old female came to the breast Cancer Clinic of our hospital
- She had a history of long term use of contraceptive pills and a mother who died at the age of 45, due to breast cancer
- 4 months after delivery, during lactation, she presented a palpable mass, well defined in mammography
- The ultrasound examination showed a breast cyst of 6cm with a thickening of the wall and another cyst of 1.5cm in the same breast.

a) Cyst of 6cm



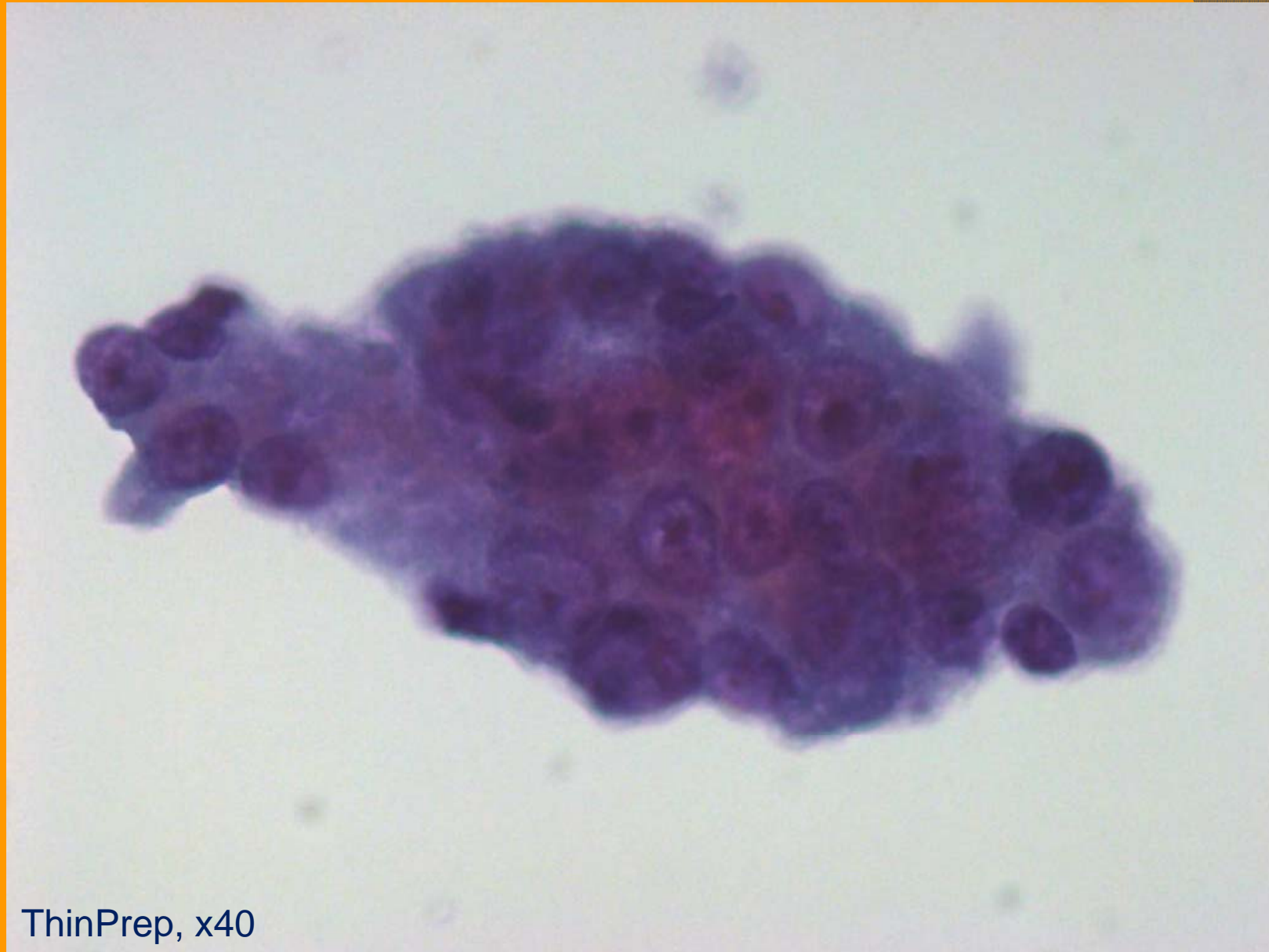
Conventional, x40

a) Cyst of 6cm



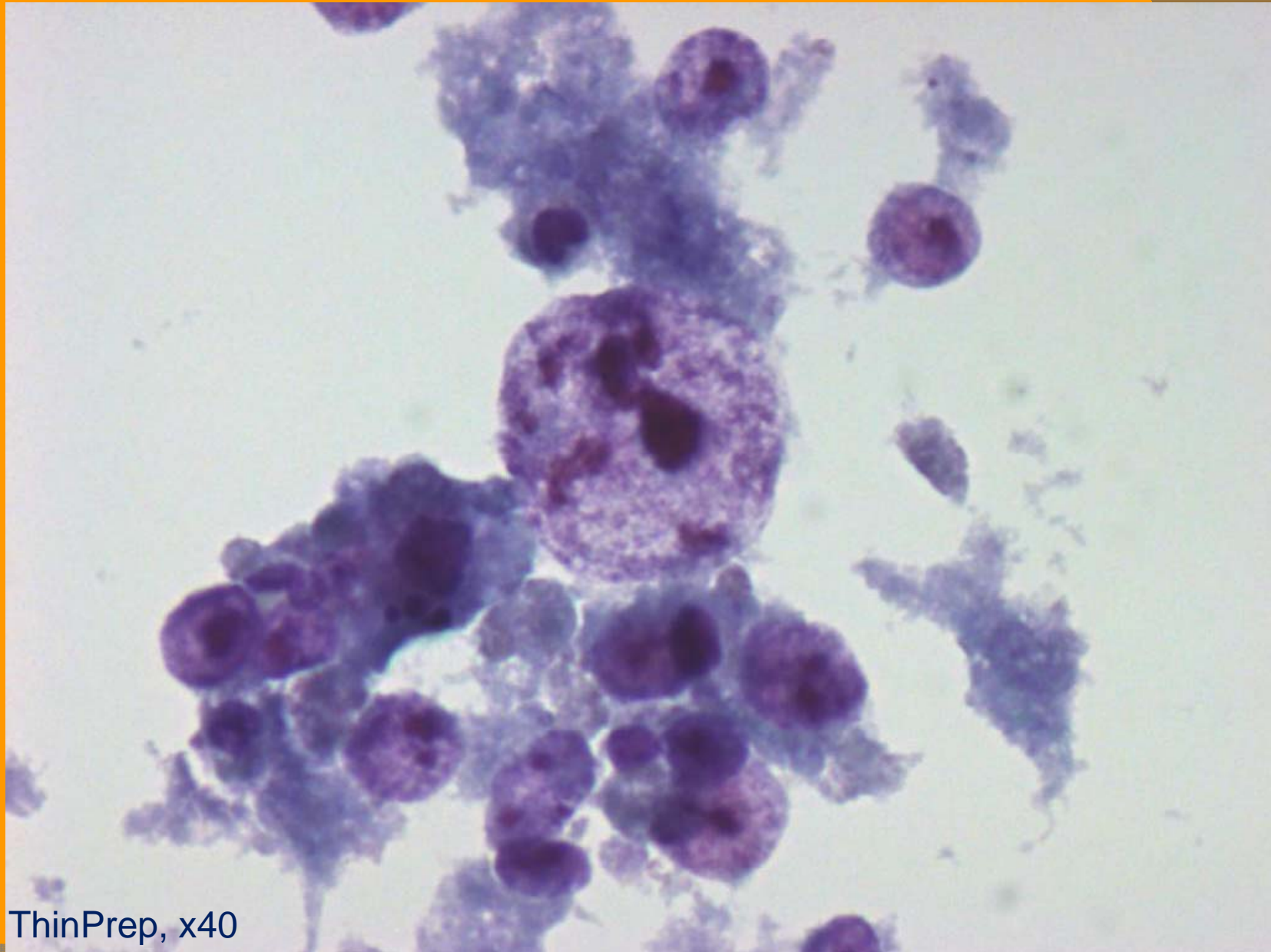
Conventional, x40

b) Cyst of 1.5cm



ThinPrep, x40

b) Cyst of 1.5cm



ThinPrep, x40