

37th European Congress of Cytology



Dubrovnik-Cavtat, Croatia

30th September - 3rd October 2012



SLIDE SEMINAR BREAST

Gordana Kaic

Merkur University Hospital

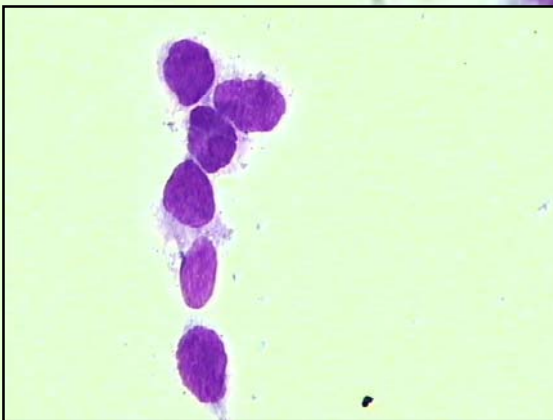
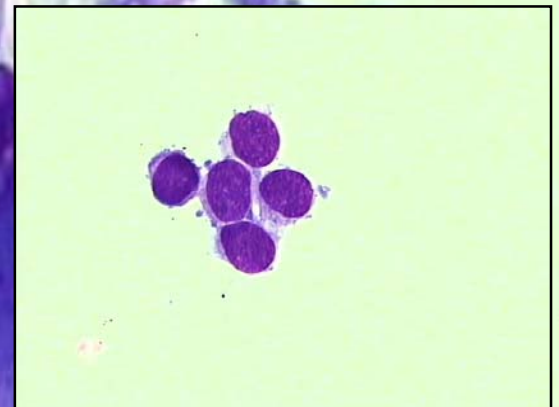
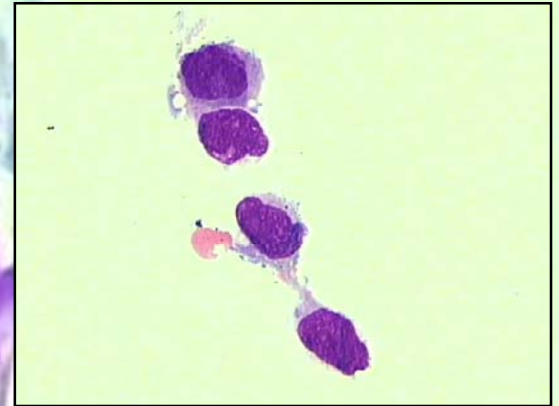
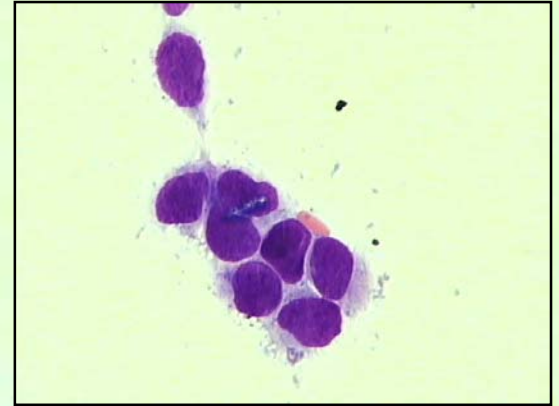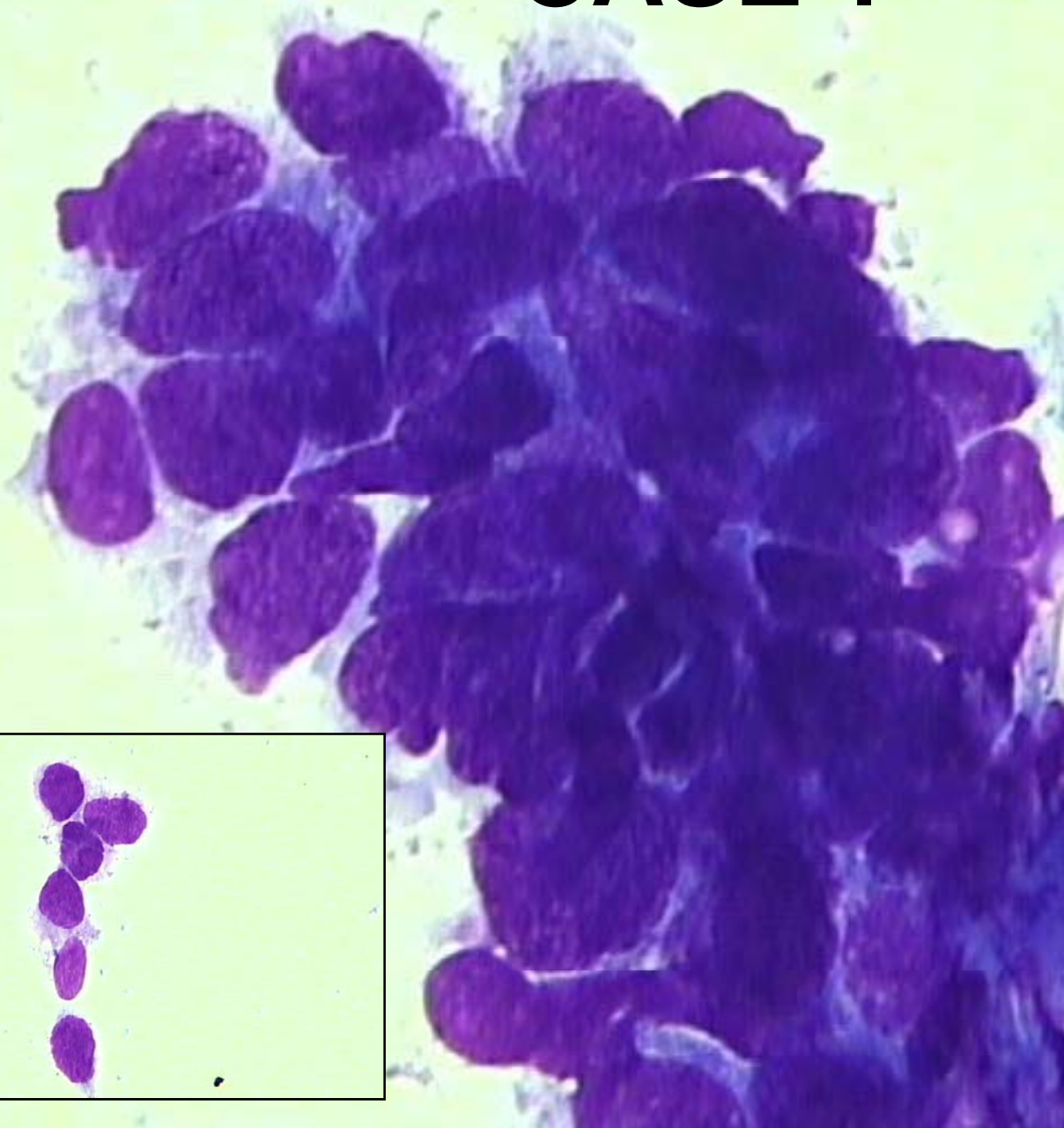
Zagreb, Croatia

CASE 1

HISTORY

- **39 yrs old female**
- **3 mth earlier regular sonography revealed normal results**
- **Sudden onset of diffuse enlargement of the right breast without any obvious reason**
- **After sonography, mamography and MRI, FNA was performed**

CASE 1



CASE 1

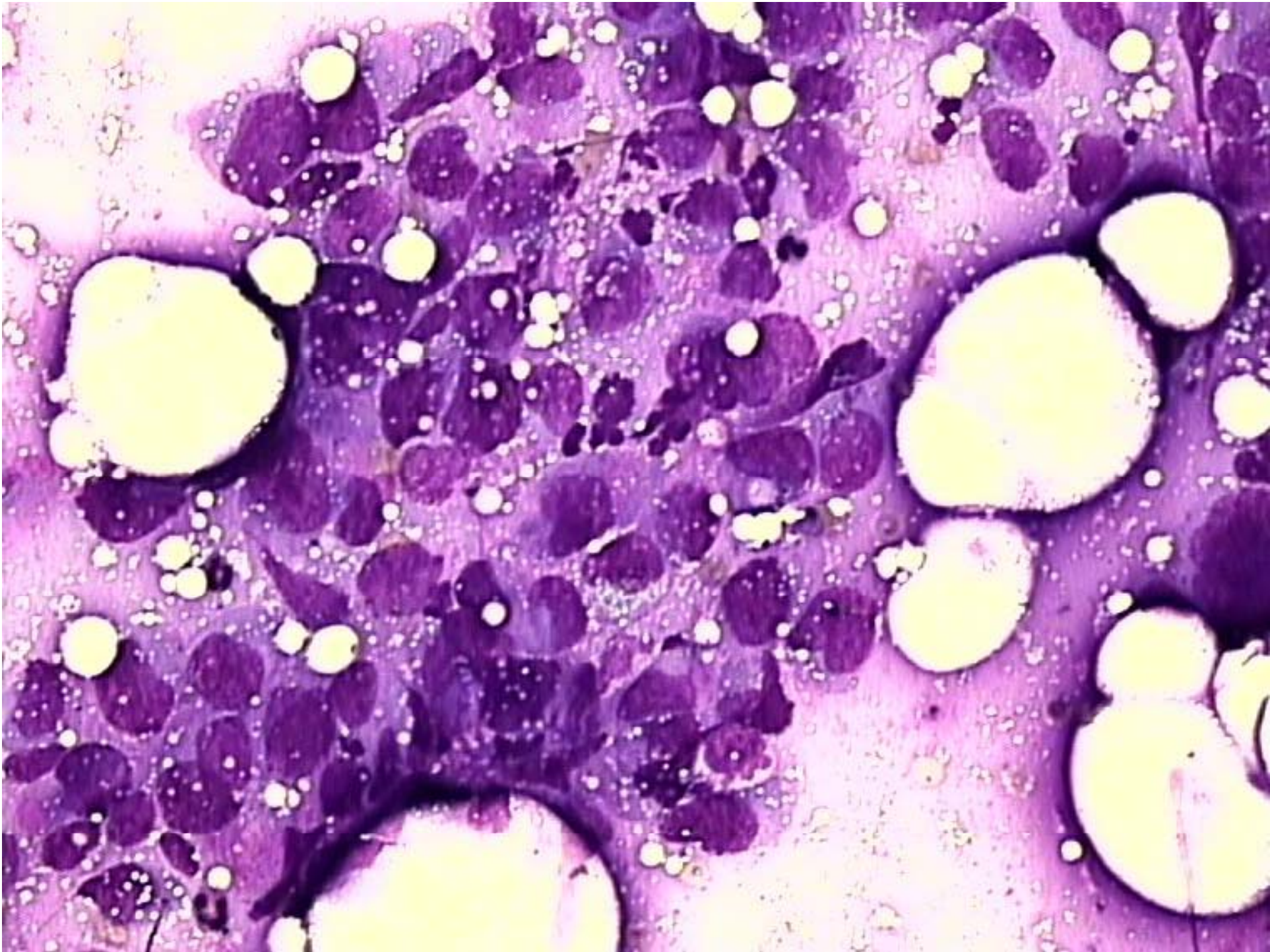
DIFFERENTIAL DIAGNOSIS

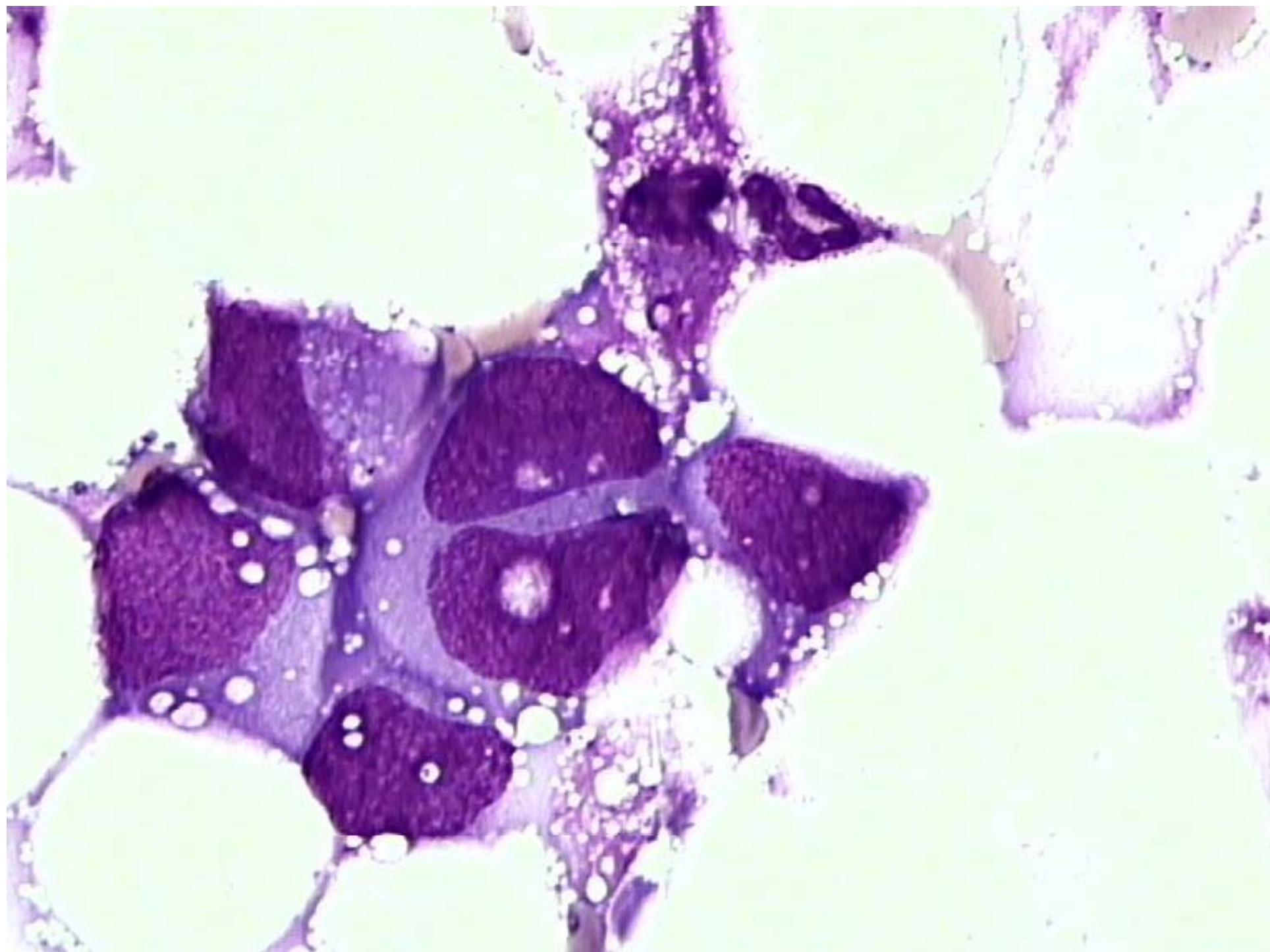
- **BENIGN EPITHELIAL PROLIFERATION**
- **ATYPICAL DUCTAL HYPERPLASIA**
- **DCIS**
- **INVASIVE CARCINOMA**

CASE 2

HISTORY

- **15 yrs old girl**
- **Palpable lump in the right breast**





CASE 2

DIFFERENTIAL DIAGNOSIS

- **MALIGNANT MESENCHYMAL TUMOR**
- **POORLY DIFFERENTIATED EPITHELIAL TUMOR**
- **MALIGNANT LYMPHOMA**