

# SLIDE SEMINAR BONE MARROW

Sandra Kojić Katović, MD, PhD

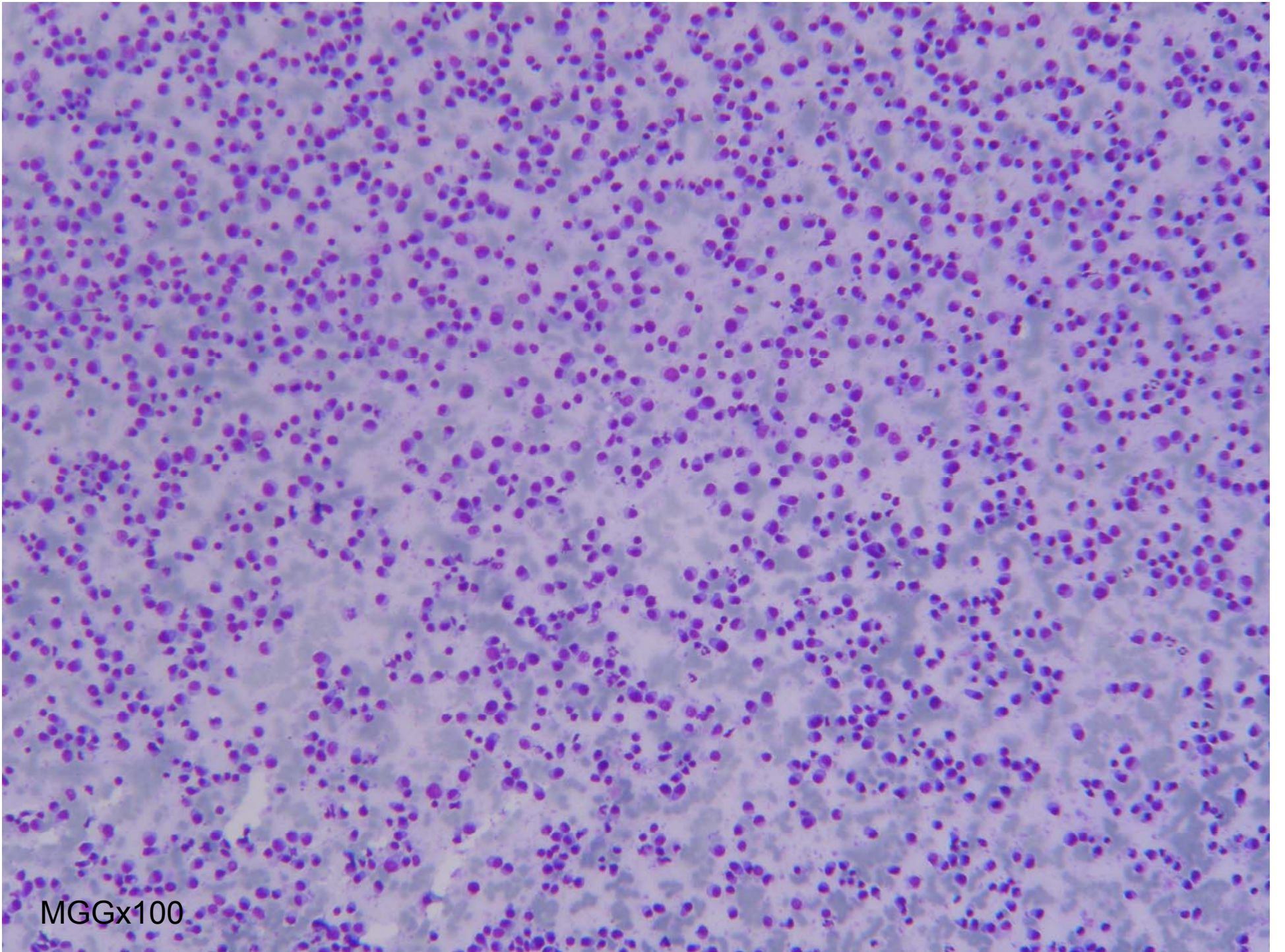
Department of cytology, “Sestre milosrdnice” University  
hospital center

# SS BONE MARROW 2

A 61-year old patient with plasmocytoma in anamnesis was submitted to cytology because of the two palpable subcutaneous nodules on the thoracic wall, which were 3 cm in diameter

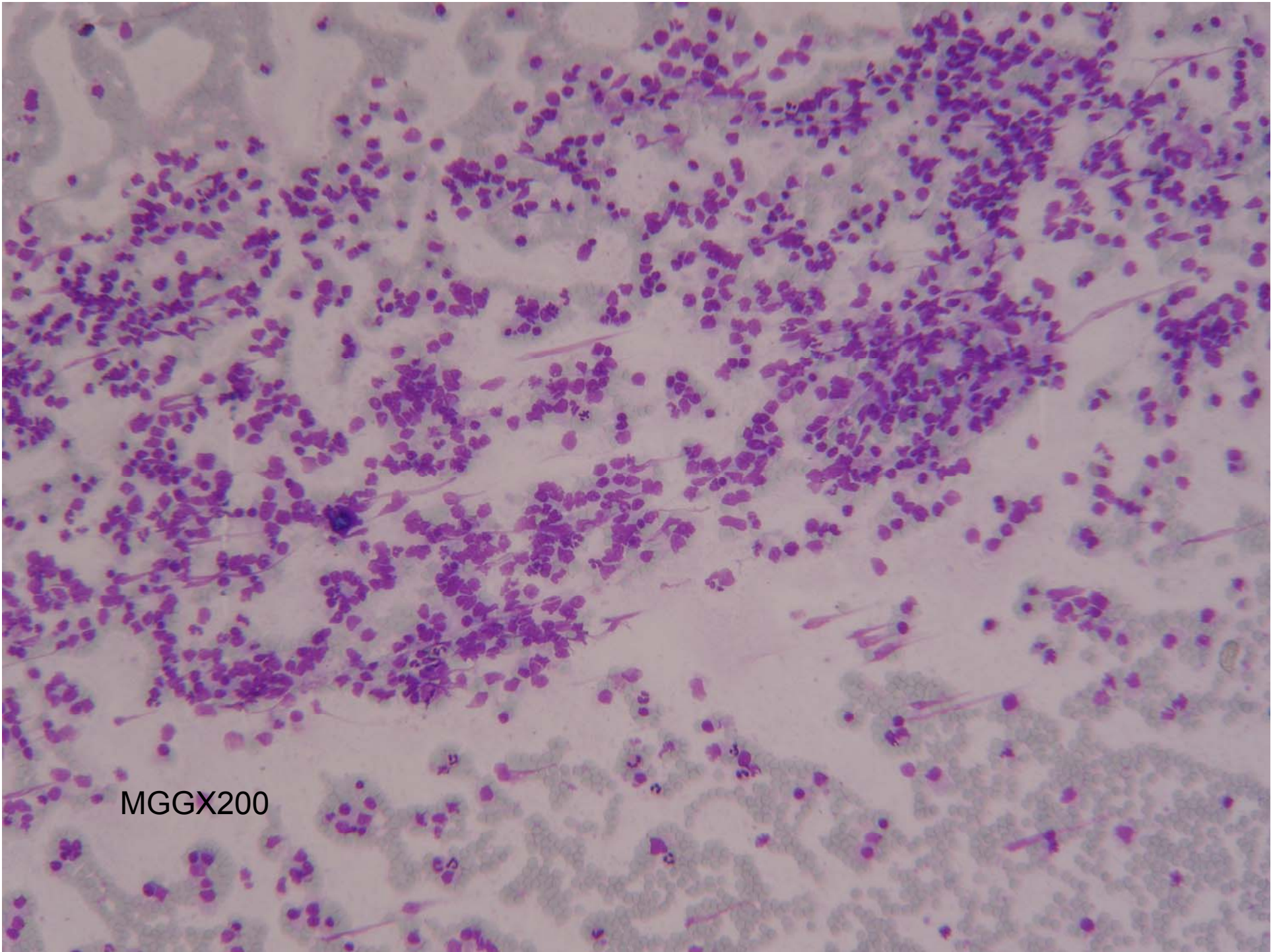
# SS BONE MARROW 2

- Laboratory findings: sedimentation rate was 27, RBC 4,2, Hb 130, WBC 9,1, PLT 217
- total protein count was 85 (norm. 66-81), without M protein in electrophoresis



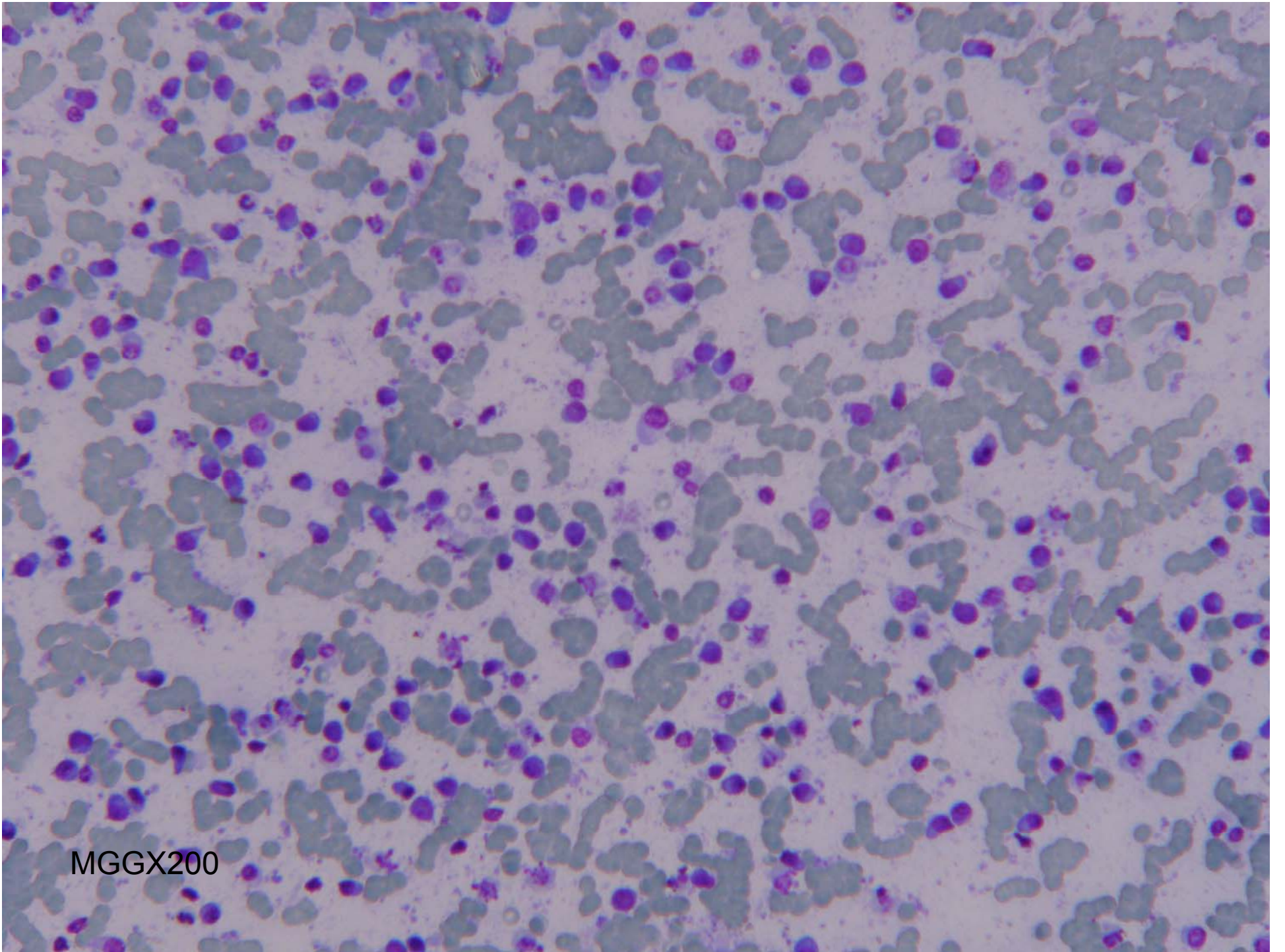
MG1636x100





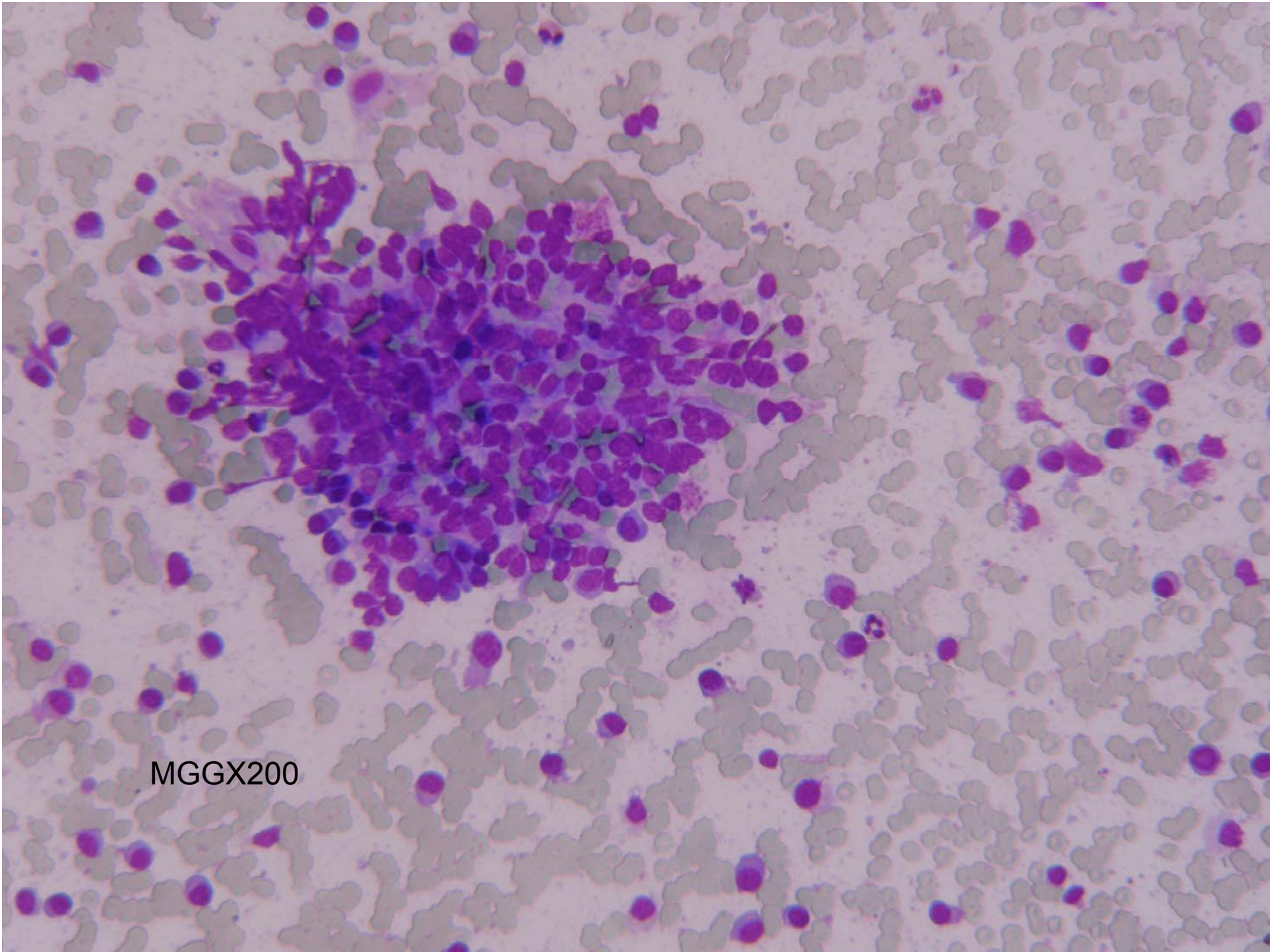
MGGX200





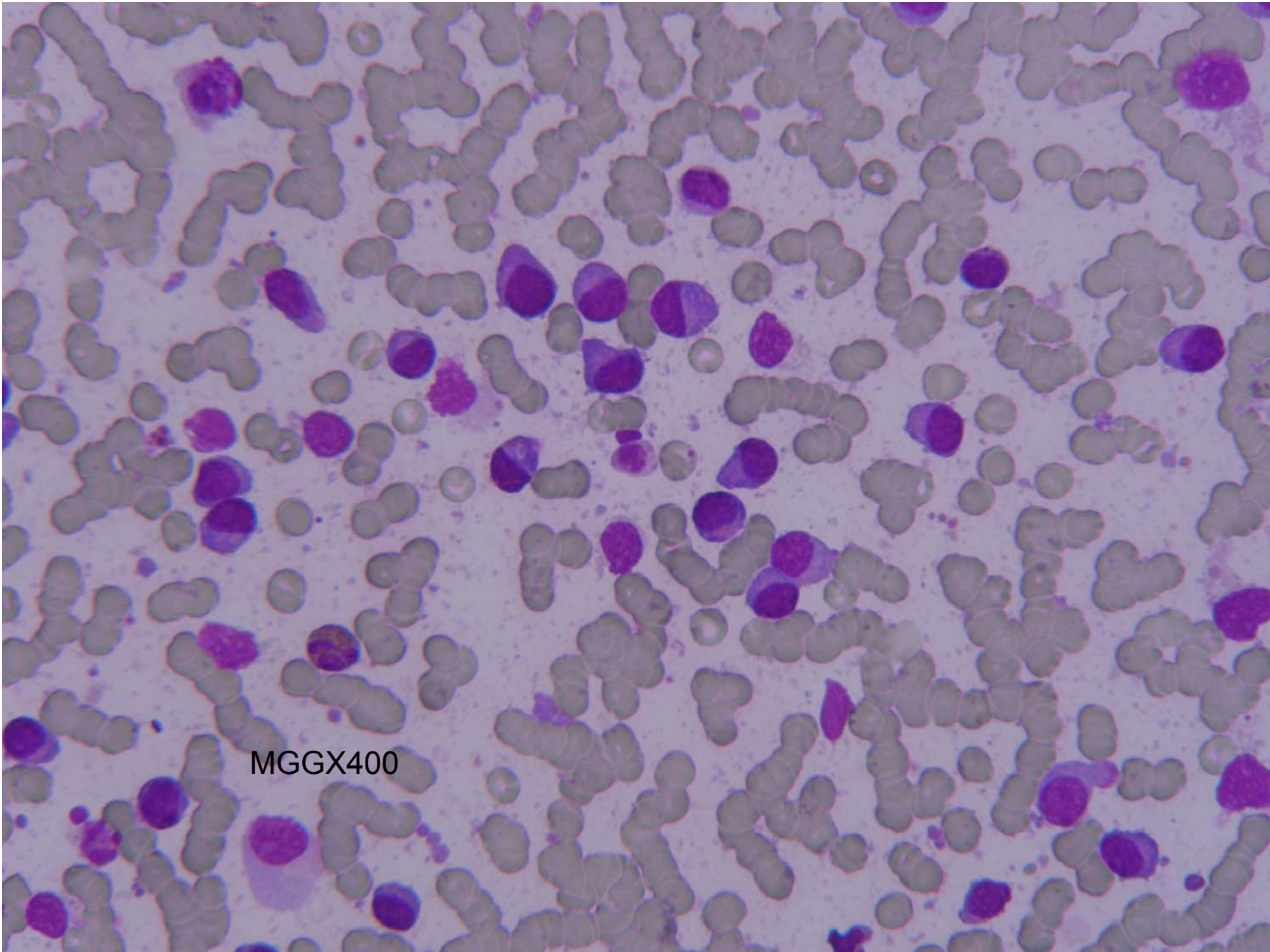
MGGX200





MGGX200





MGGX400