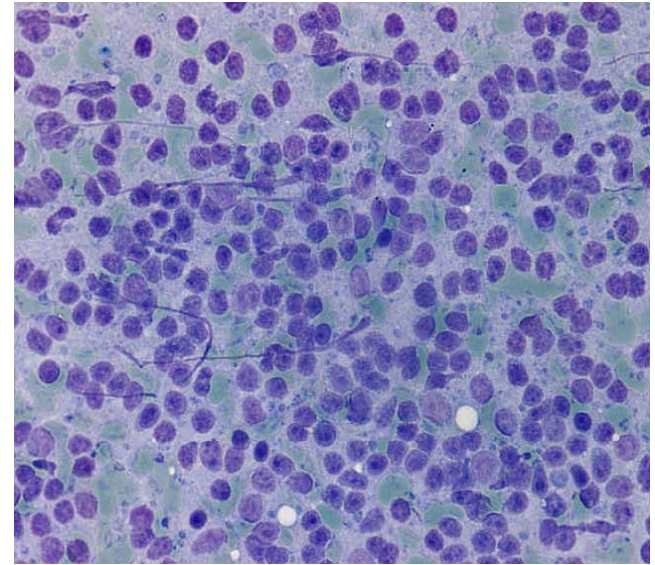


Case 2

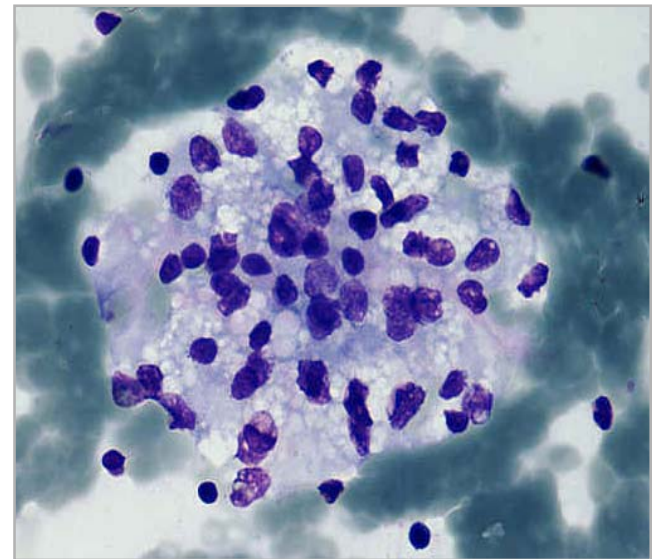
Veronika Kloboves Prevodnik, MD., PHD., Anja Grčar, MD,
Institute of Oncology, Ljubljana, Slovenia

Clinical history

- 68-year old male
- 1999: renal clear cell adenocarcinoma
 - left nephrectomy
- 2008: chronic lymphocytic leukemia (CLL)
- 13 months after diagnosis of CLL: metastasis of renal clear cell adenocarcinoma in epigastric lymph nodes
 - different chemotherapy for CLL
 - Sunitinib for metastatic renal cell carcinoma
- recently : high fever and chills, fatigue, pancytopenia, LDH (31.66) and renal insufficiency
- UZ-FNAB of left iliac lymph node and bone marrow aspiration were performed

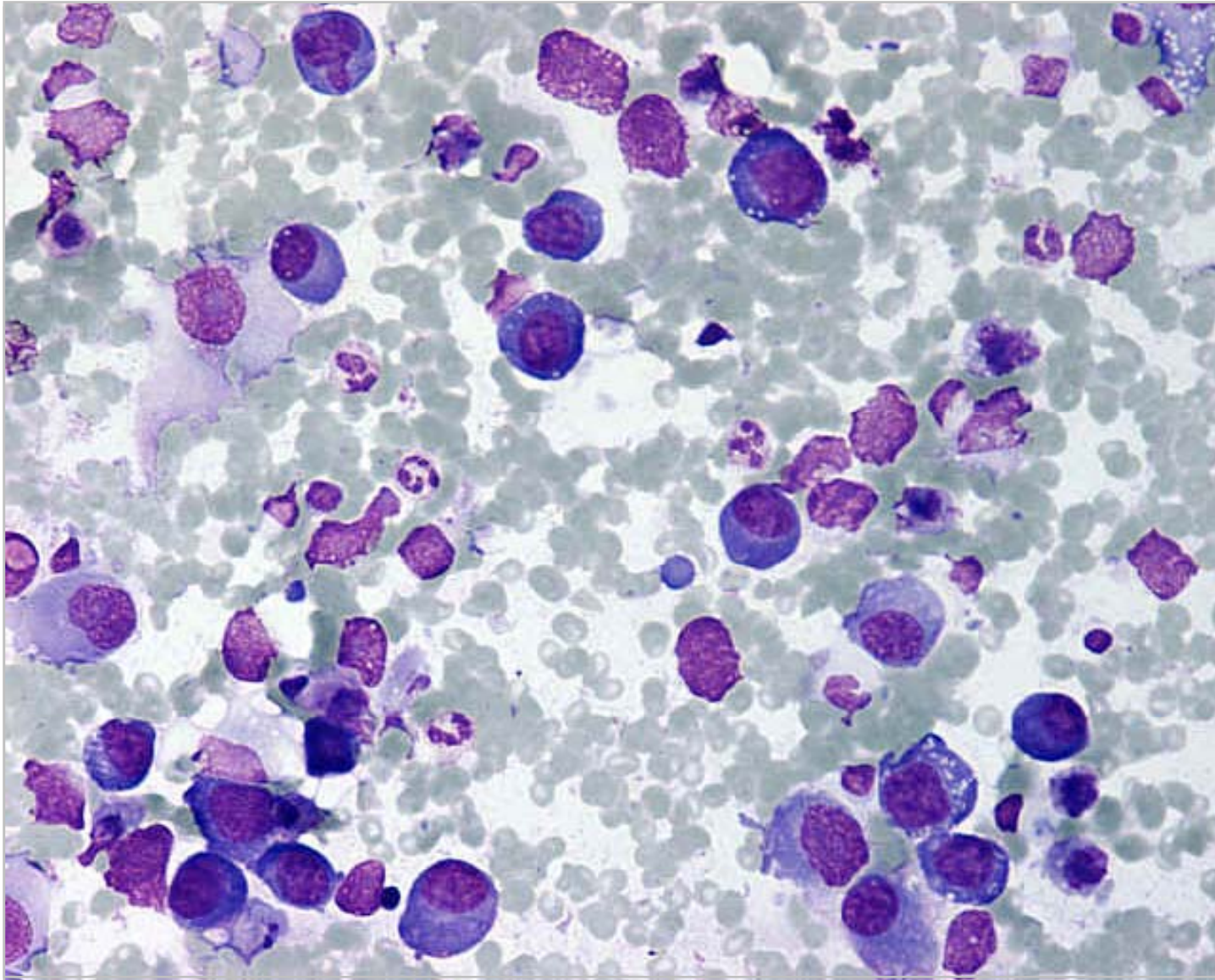


CLL

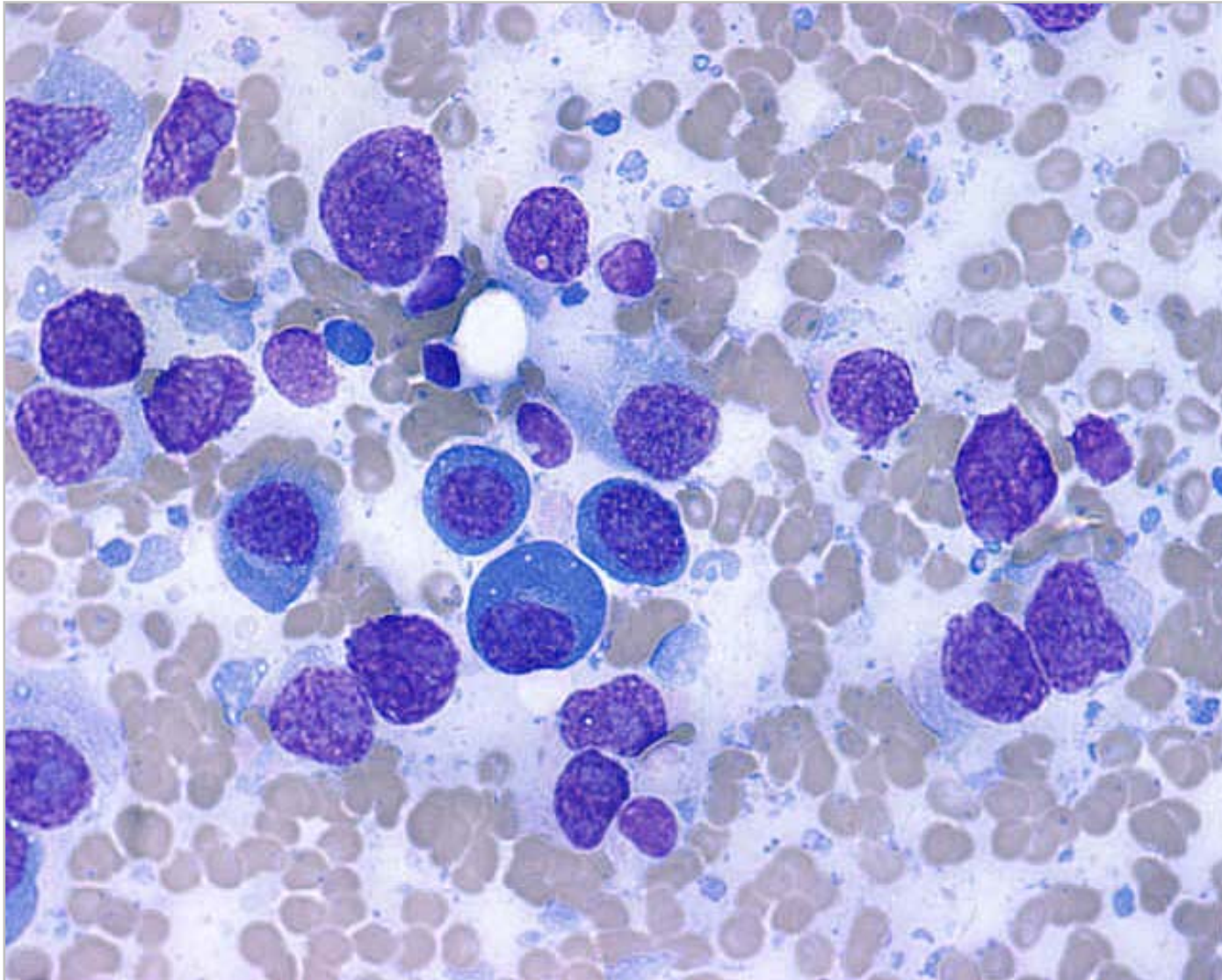


METASTATIC RENAL CELL
ADENOCARCINOMA

Left iliac lymph node (UZ-FNAB)



Bone marrow (aspiration biopsy)



What is your
diagnosis?