

Case 1

Veronika Kloboves Prevodnik, MD. PhD.

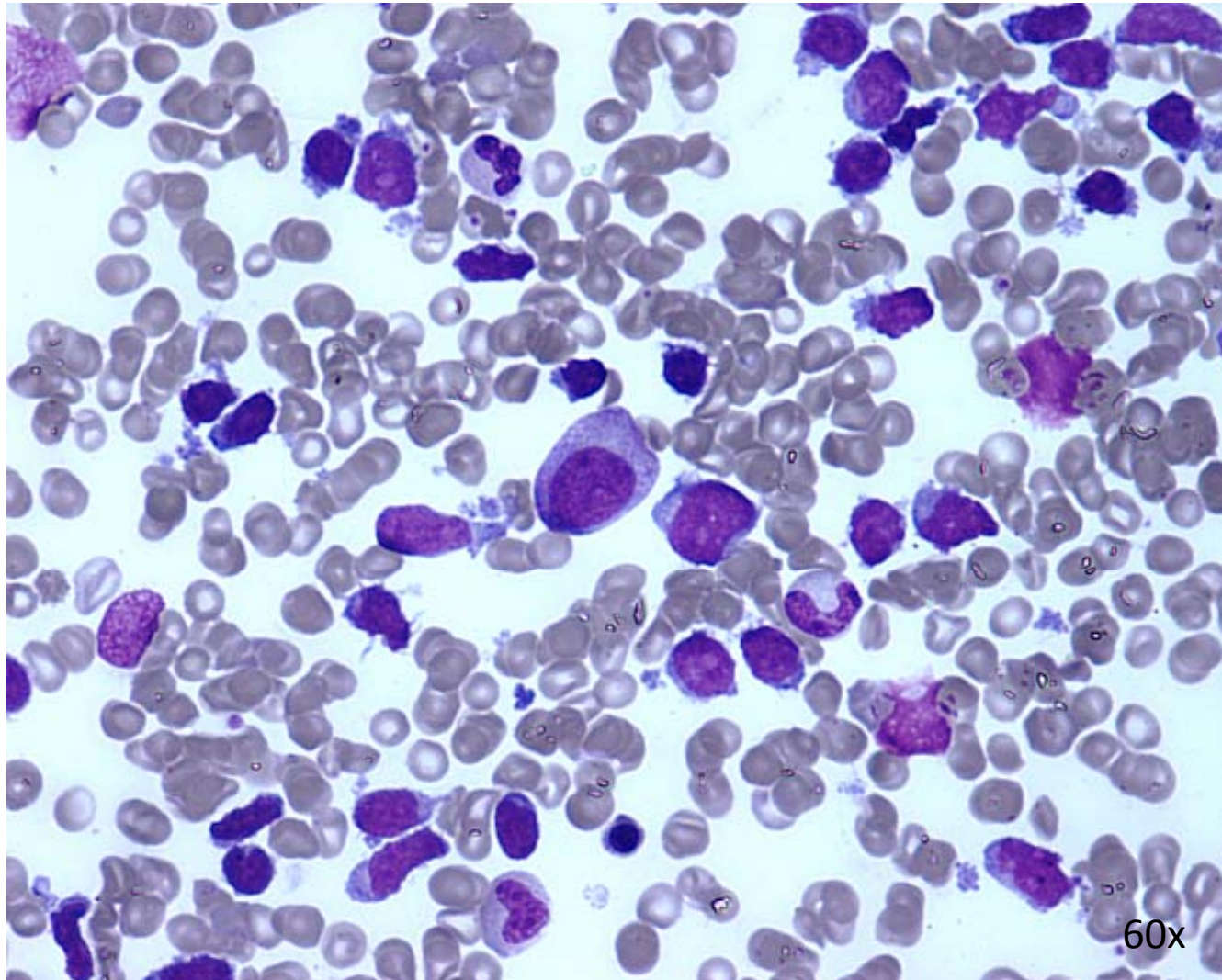
Institute of Oncology

Ljubljana, Slovenia

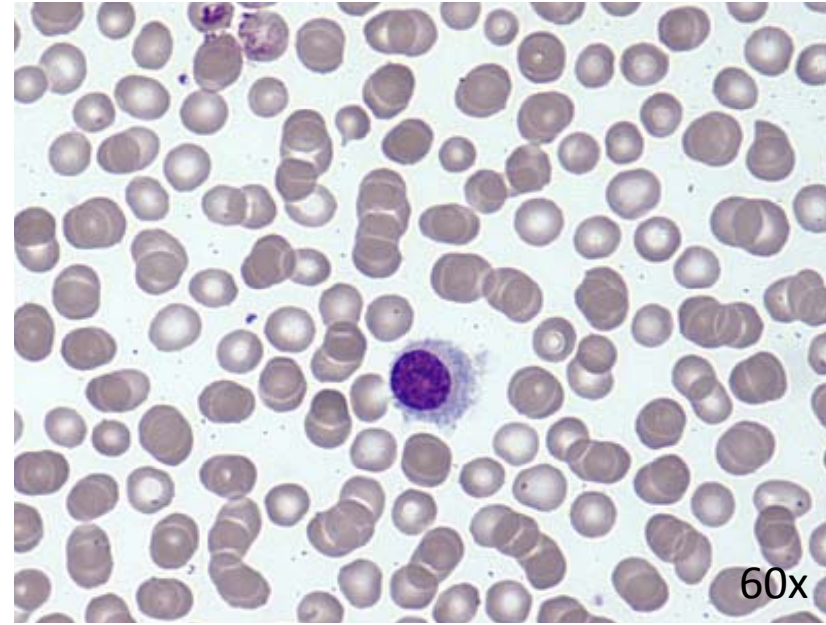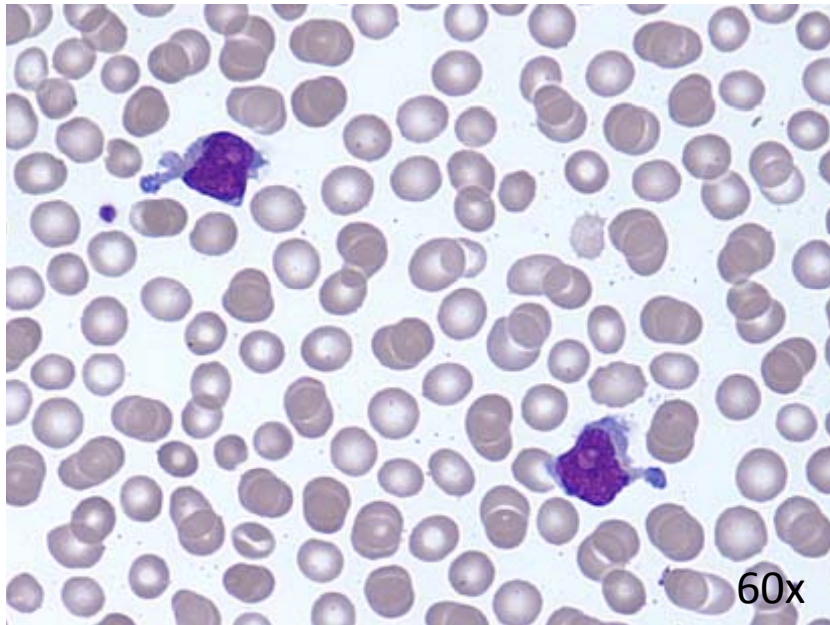
Case history

- 53-year –old women complained for fatigue, tenderness of the abdomen and high body temperature (about 39°C) for 2.5 months
- clinical findings
 - hepatosplenomegaly,
 - slightly enlarged inguinal and axillary lymph nodes,
 - petechiae in thorax and thigh,
- hematological findings
 - leukopenia ($3 \times 10^9/l$),
 - anemia (Hb 115 g/l),
 - thrombocytopenia ($64 \times 10^9/l$)
 - atypical lymphoid cells in peripheral blood smear
- surgical biopsy of left inguinal lymph node
 - peripheral T-cell lymphoma with cytotoxic immunophenotype
- bone marrow aspiration and trephine biopsy and FNAB of axillary lymph node were performed for staging

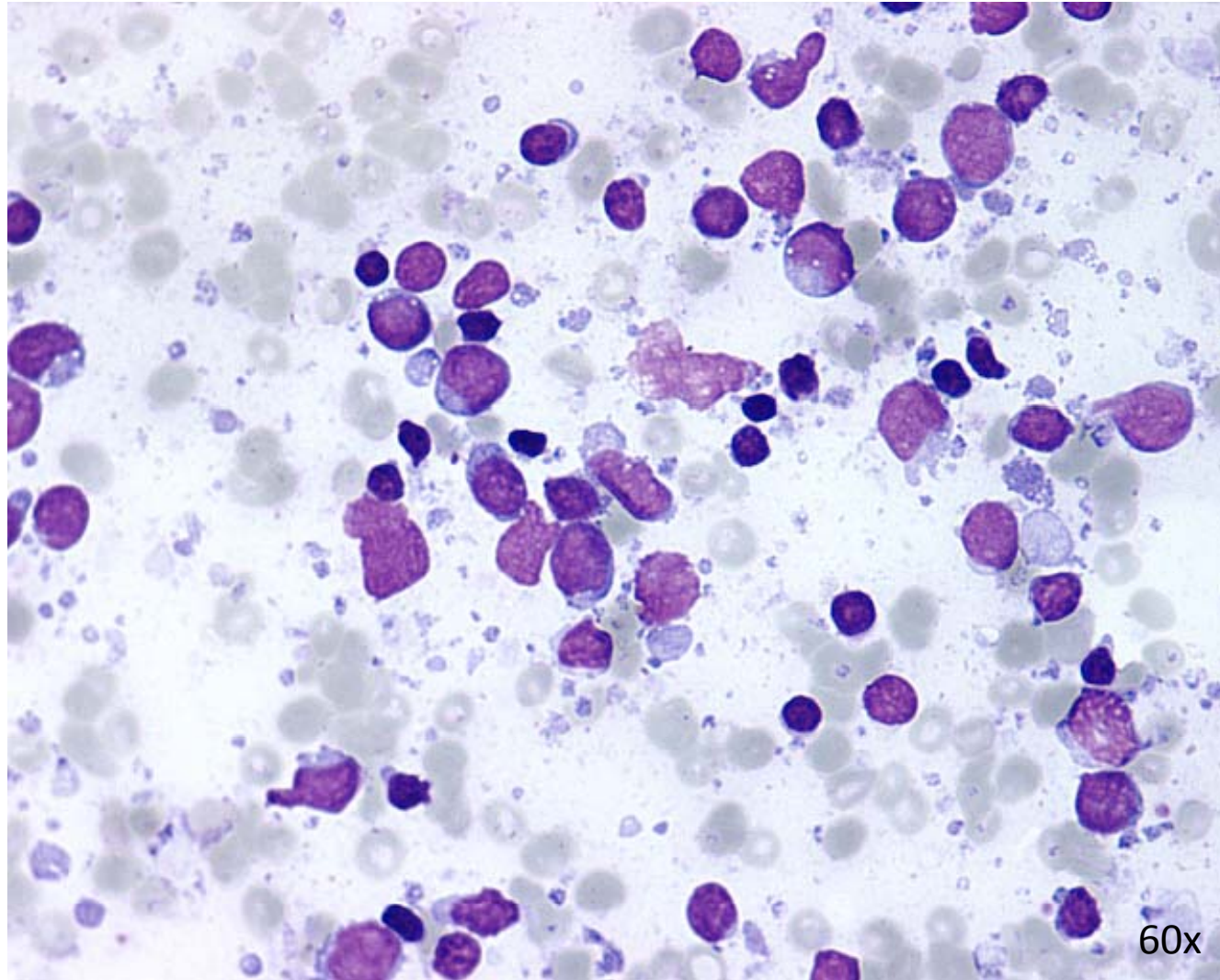
Bone marrow



Peripheral blood



FNAB of axillary lymph node



What is your diagnosis?

