



Dubrava University Hospital  
Zagreb, Croatia

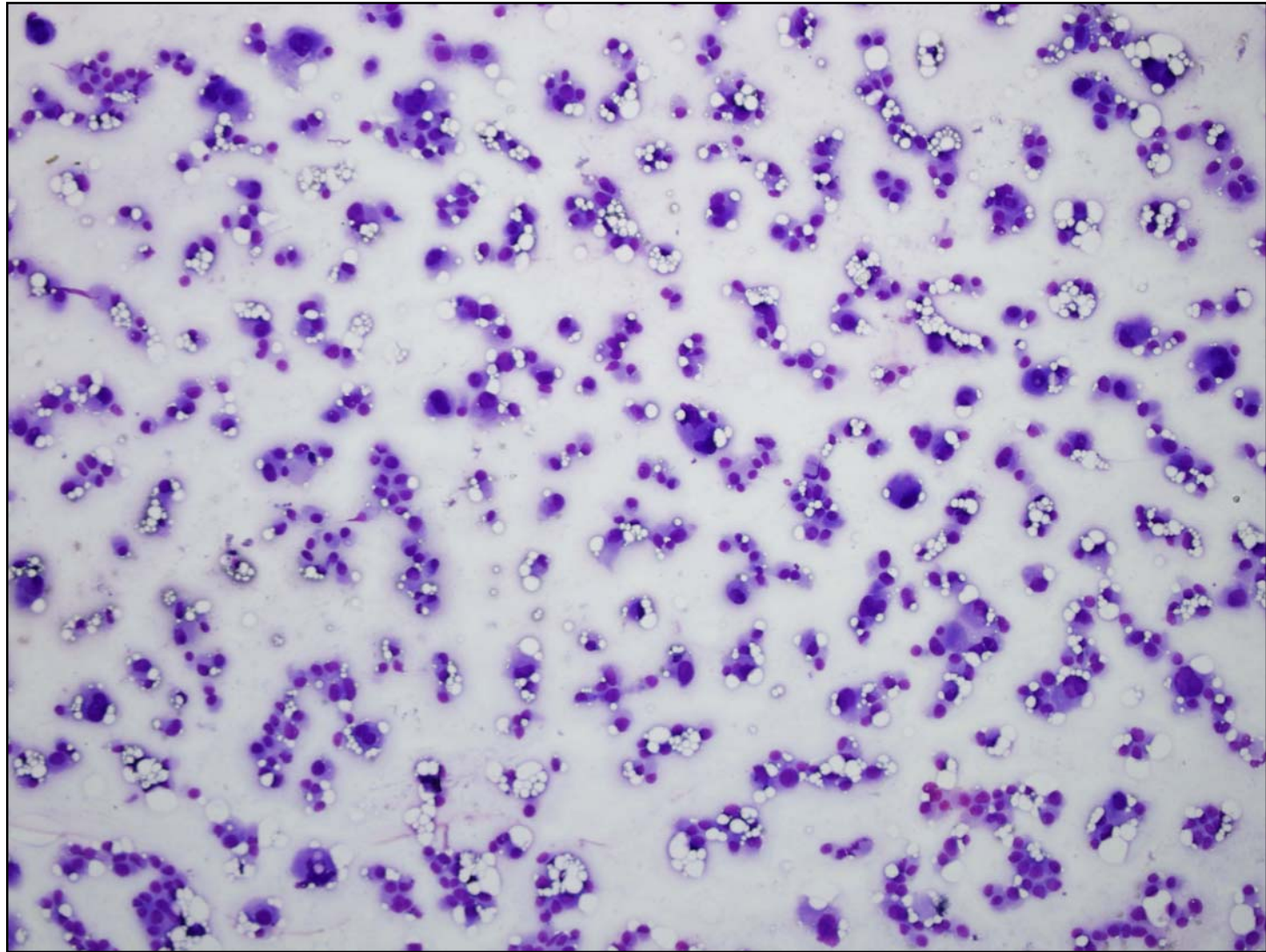
# SLIDE SEMINAR LYMPH NODE

KARMEN TRUTIN OSTOVIĆ

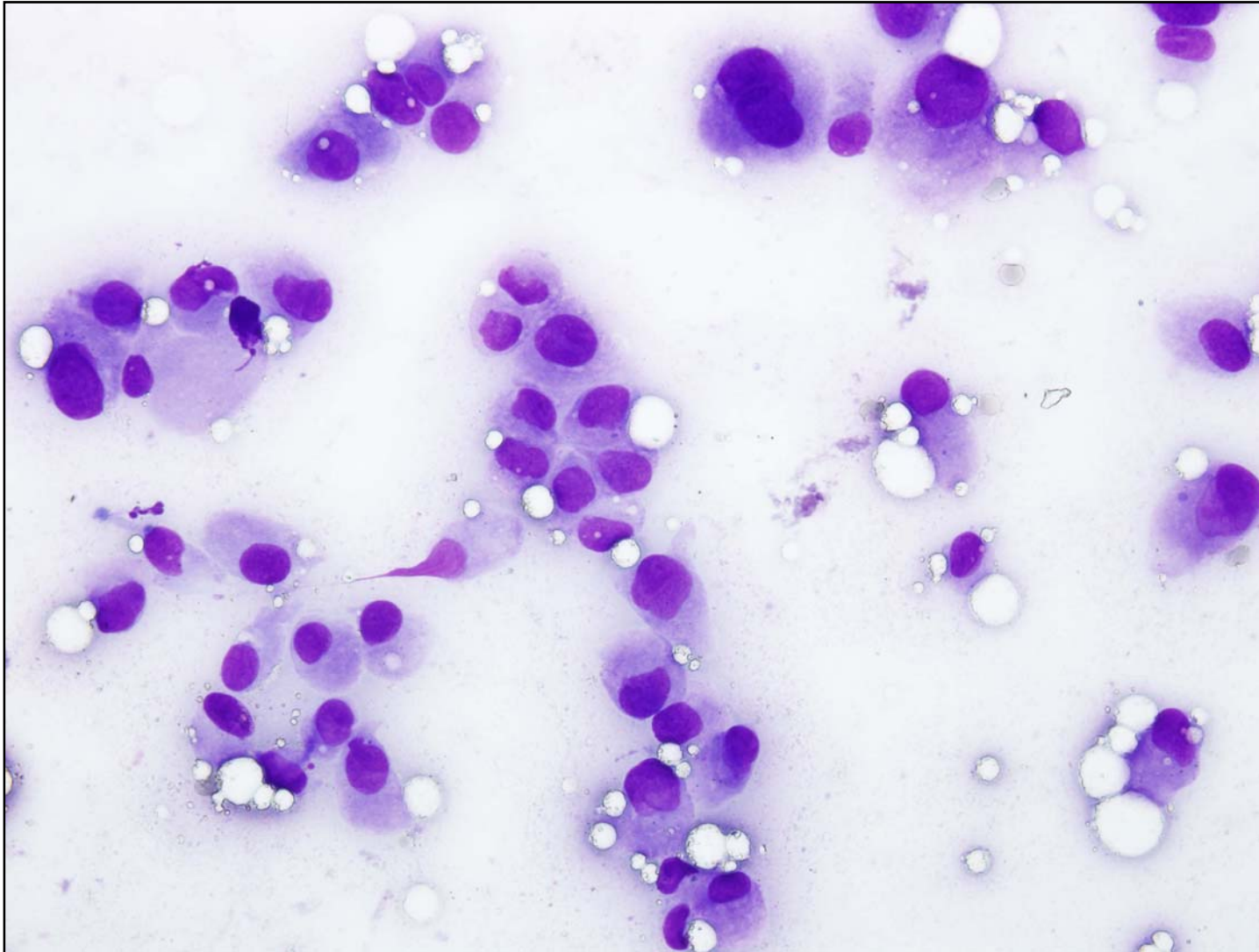
37th European Congress of Cytology,  
Cavtat, Croatia, 30th Sept – 3rd October 2012

# CASE HISTORY

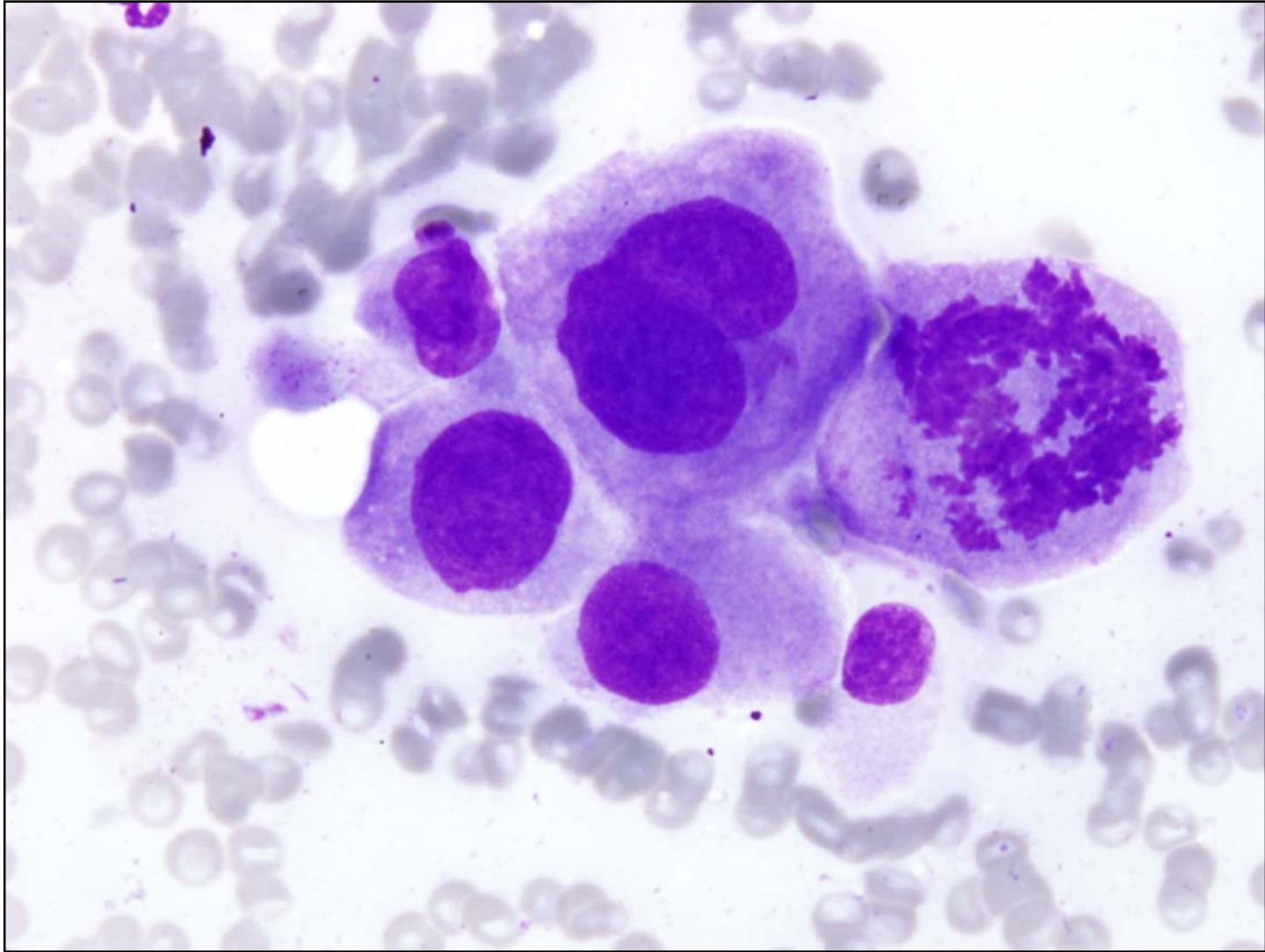
- A 77-year old man suffering of Fibrilatio atriorum paroxysmalis
- US: on the left lower part of the neck there were couple of round hypoechogenic lymph nodes
- FNA of the largest lymph node supraclavicular (10x8x10 mm)
- Smears were prepared



May-Grünwald Giemsa 100x

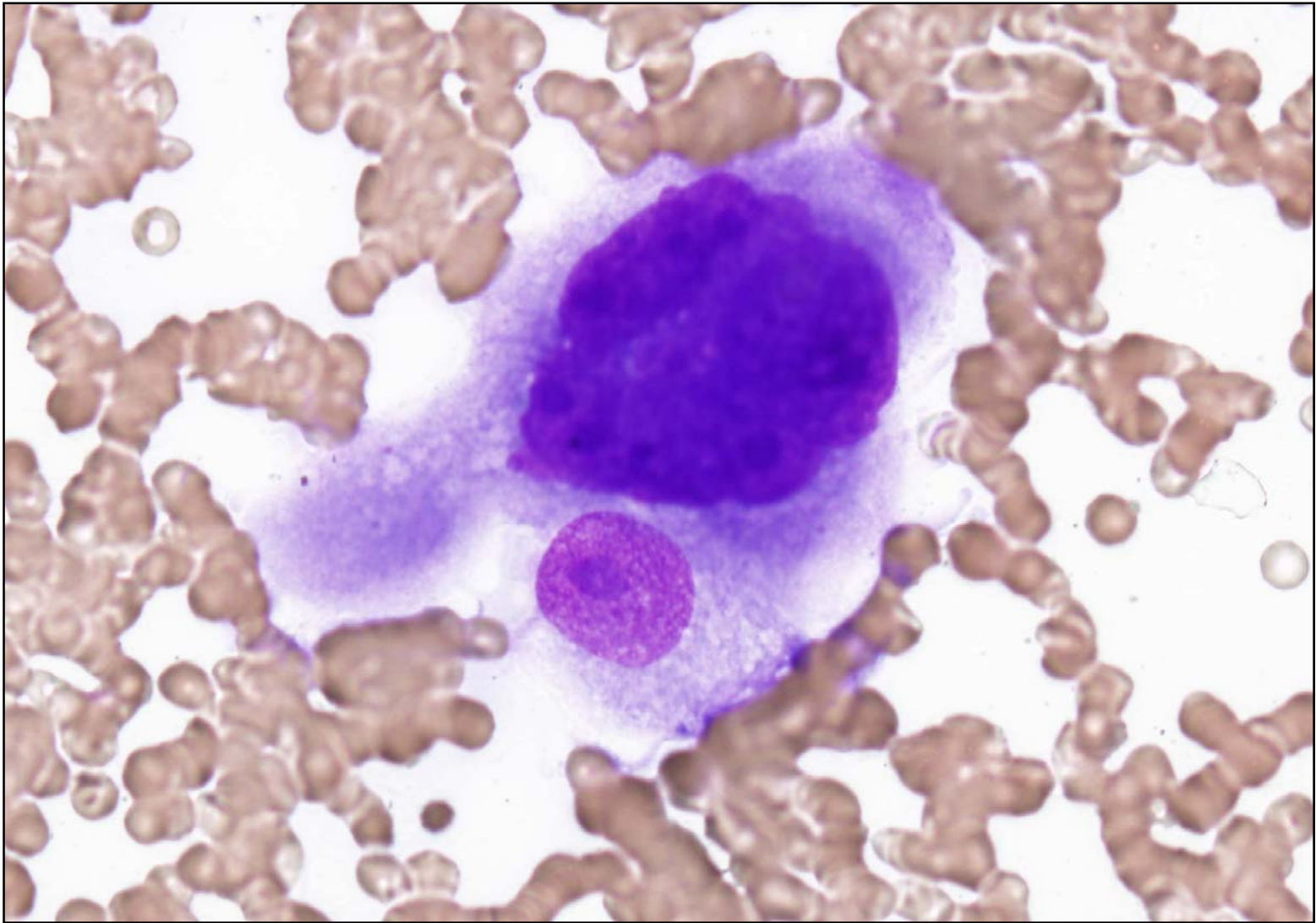


May-Grünwald Giemsa 400x



May-Grünwald Giemsa 1000x





May-Grünwald Giemsa 1000x