

37th European Congress of Cytology

Dubrovnik-Cavtat, Croatia

30th September - 3rd October 2012



SLIDE SEMINAR

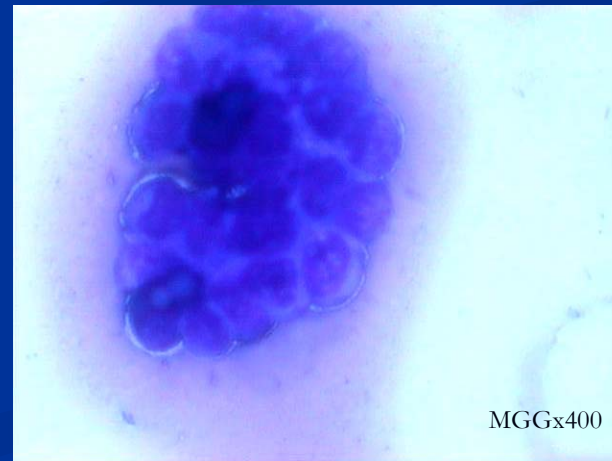
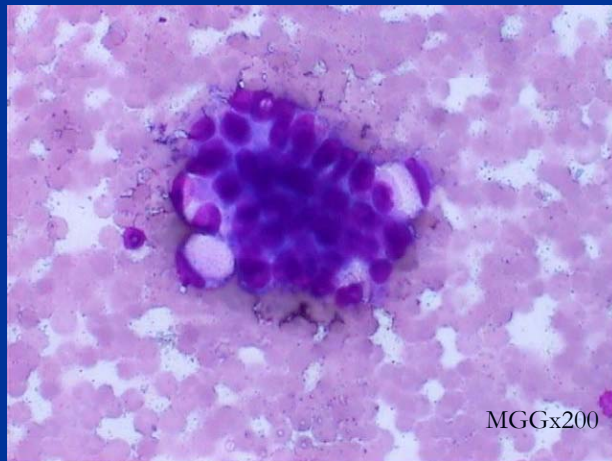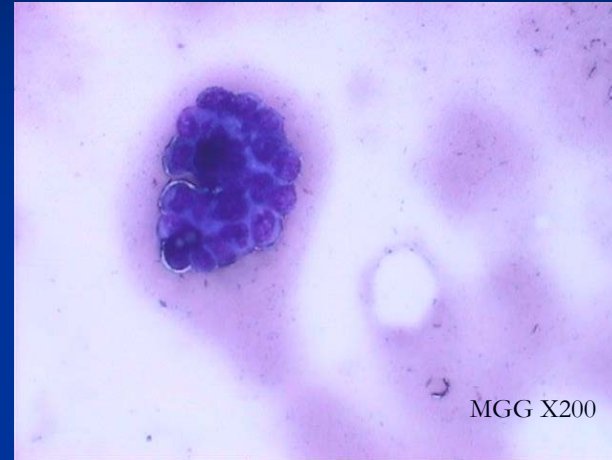
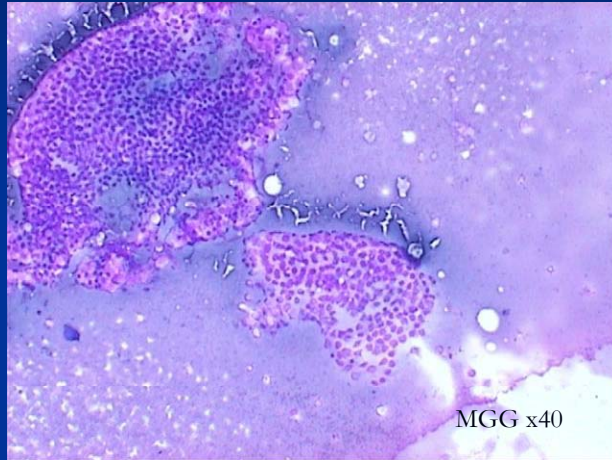
Gynecology- Ovarian tumor

Danijela Jurič

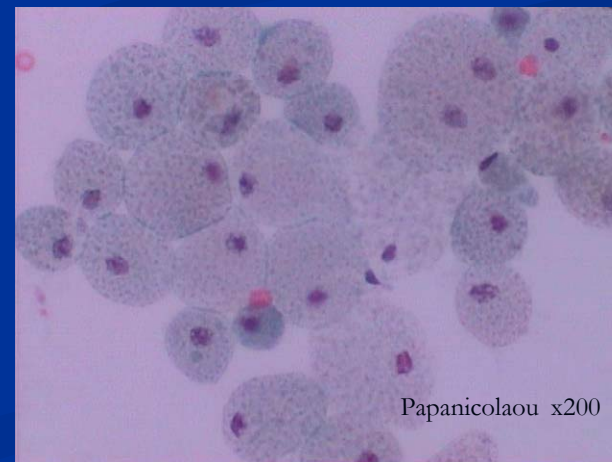
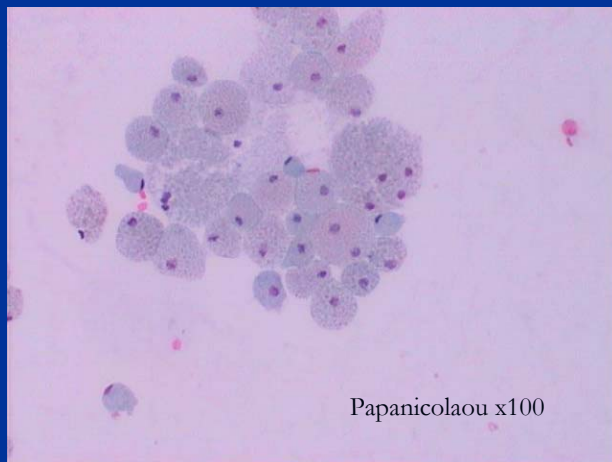
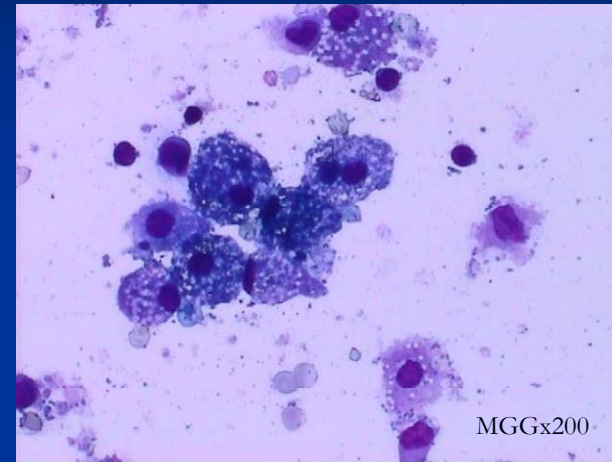
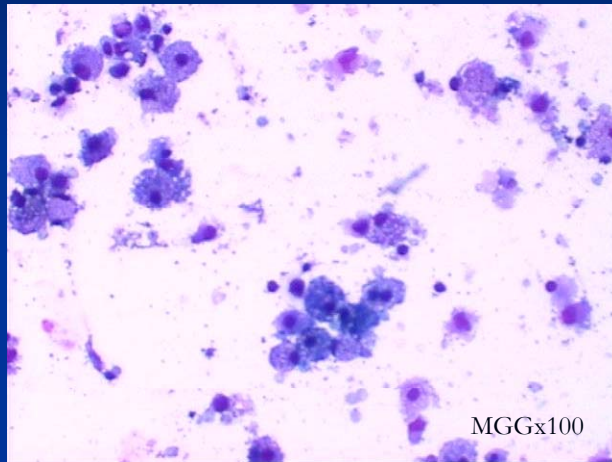
CASE – OVARIAN TUMOR

- An asymptomatic woman of 41 years old
- Regular medical examination
- Pelvic ultrasound : cystic lesion 12 cm -smoothly marginated with papillary projection measuring 1.6 cm
- Serum CA 125, CEA, CA19-9 and CA 15-3 were all within normal limits

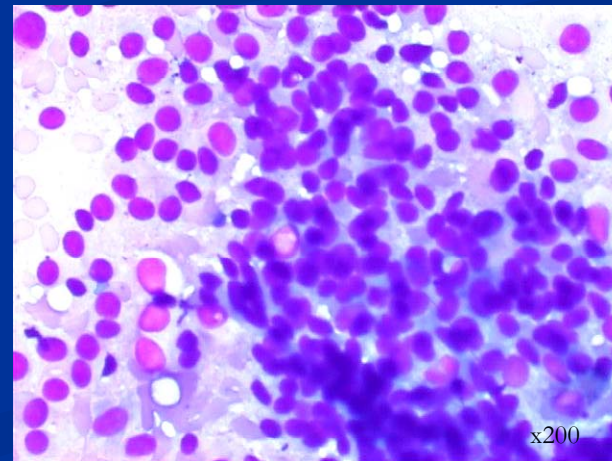
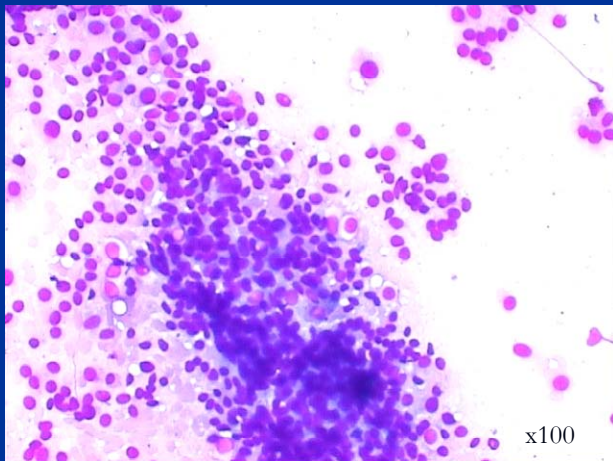
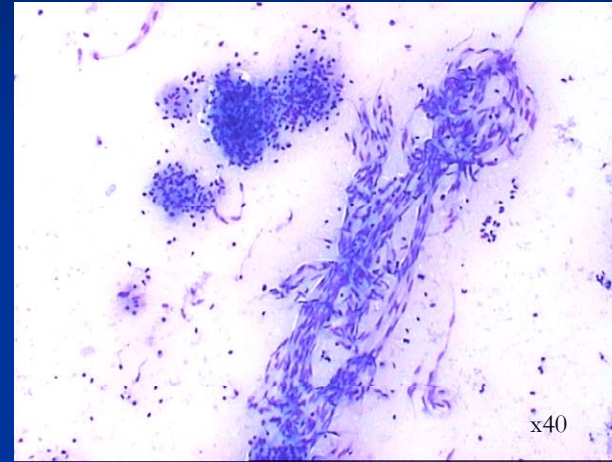
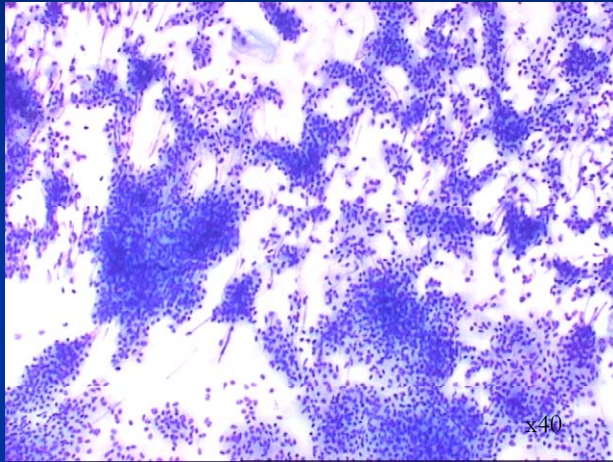
Peritoneal washing



Aspiration of cyst



Imprint slides (touch cytology) – MGG*



* May-Grünwald-Giemsa stain

Imprint slides (touch cytology) - Papanicolaou

