

Case 1

Female, 56 years old

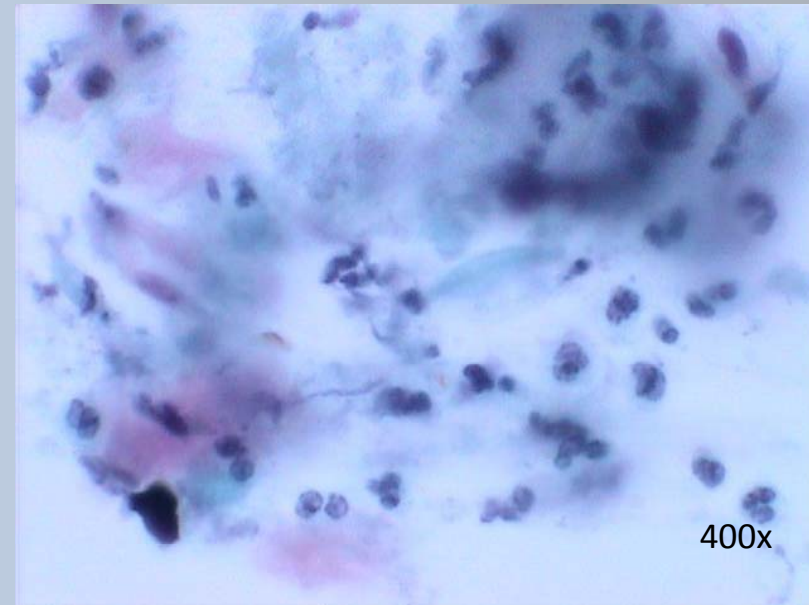
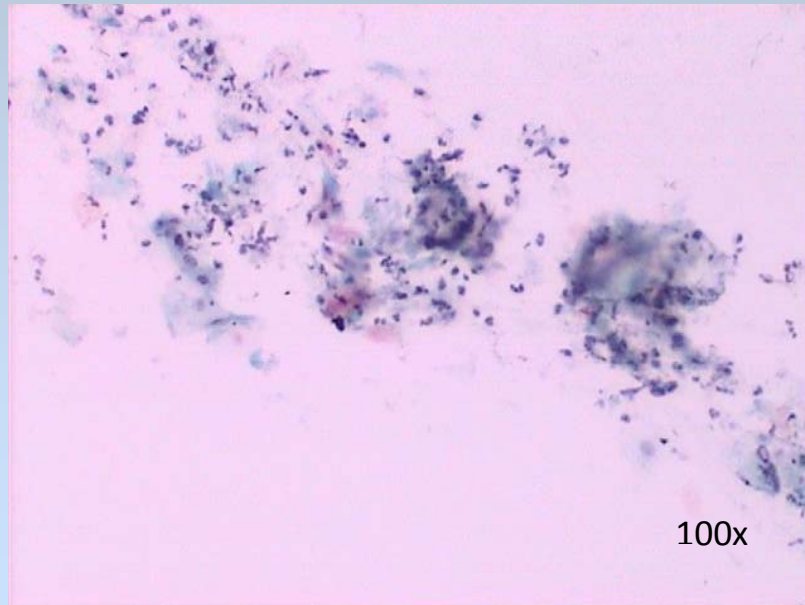
25 years ago cone biopsy: CIN III (carcinoma in situ cervicis)

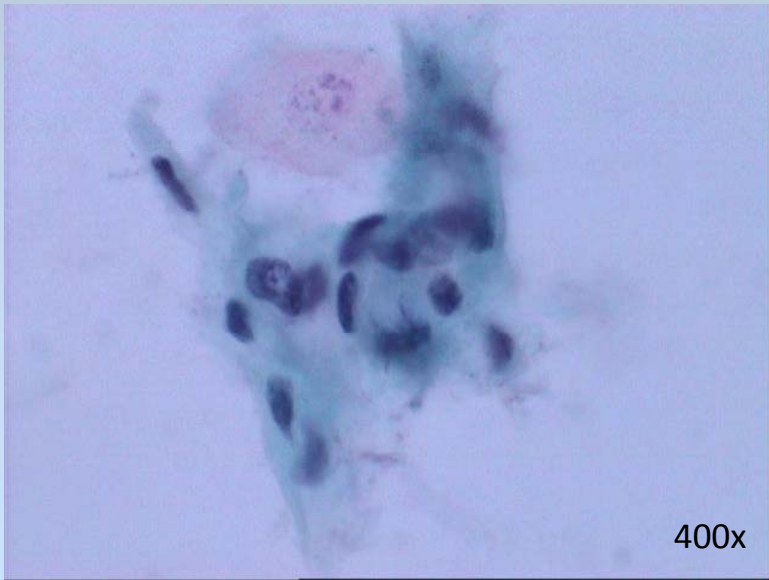
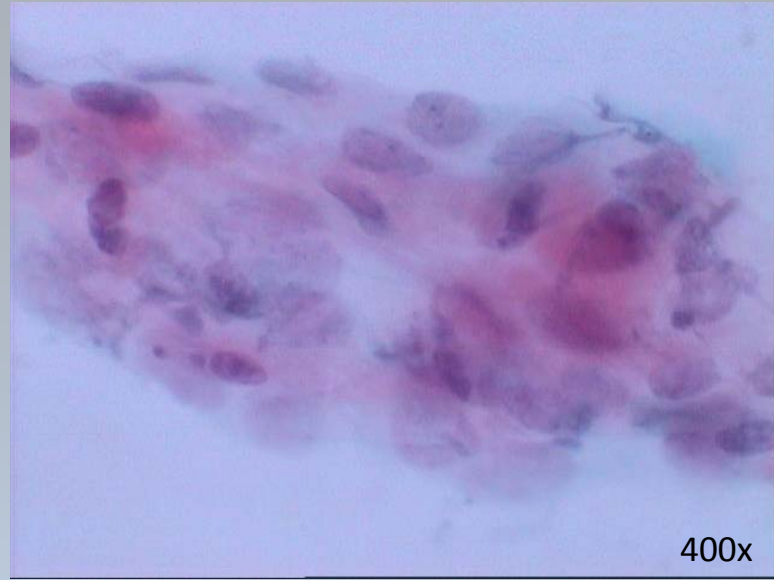
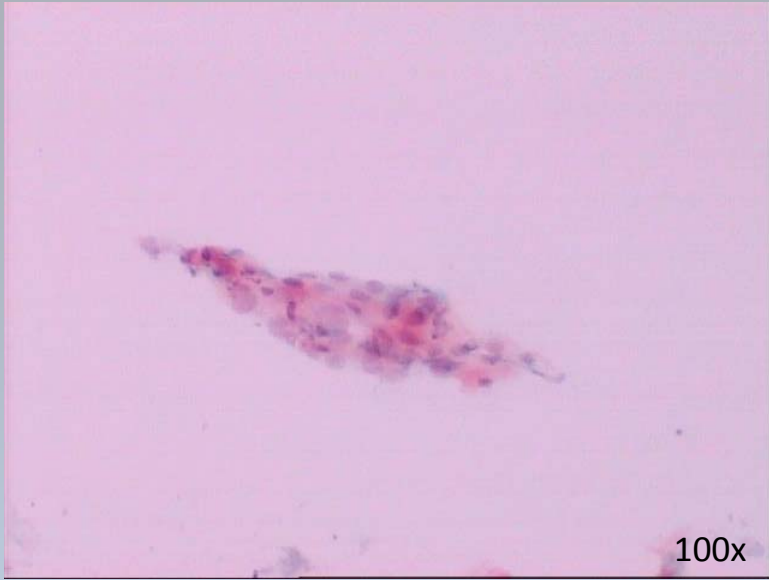18 years ago second cone biopsy: CIN III (carcinoma in situ cervicis)

symptoms: Vaginal discharge

Gynecological exam: Episiotomy erosion, cervix with an old scar

Vulvar smear:



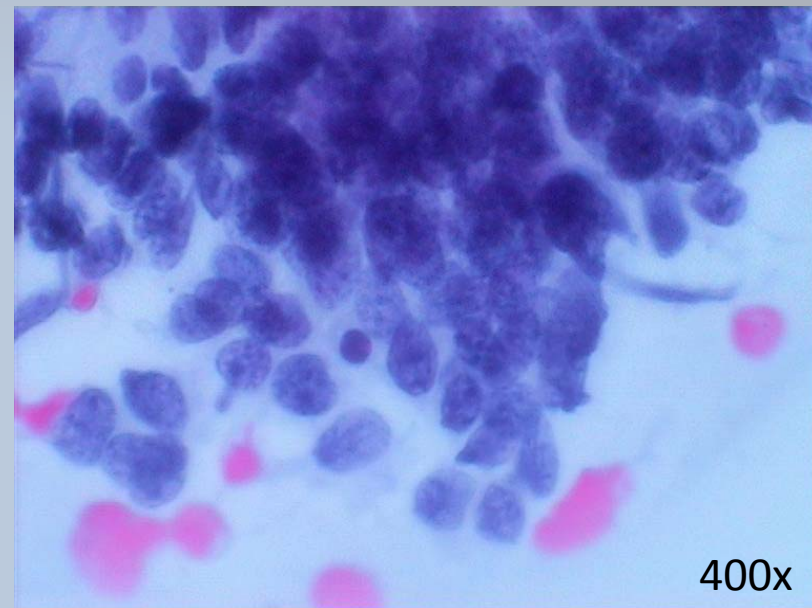
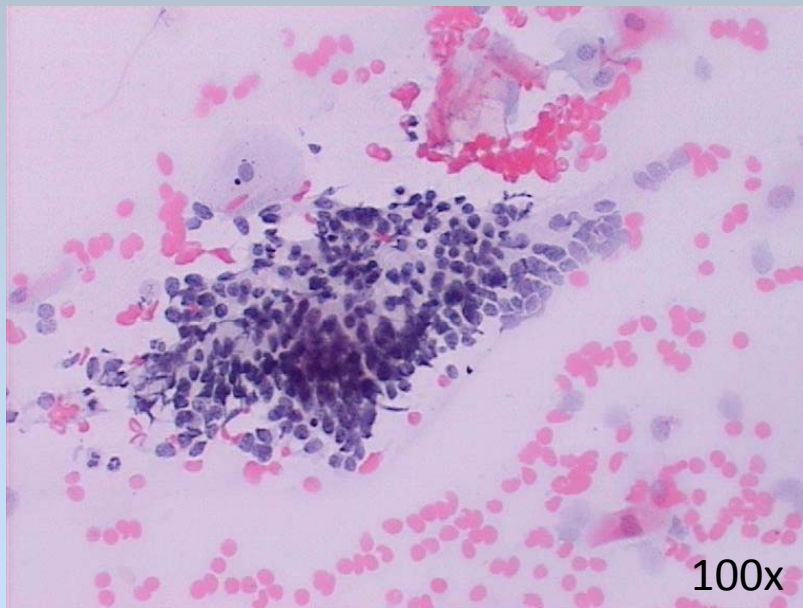


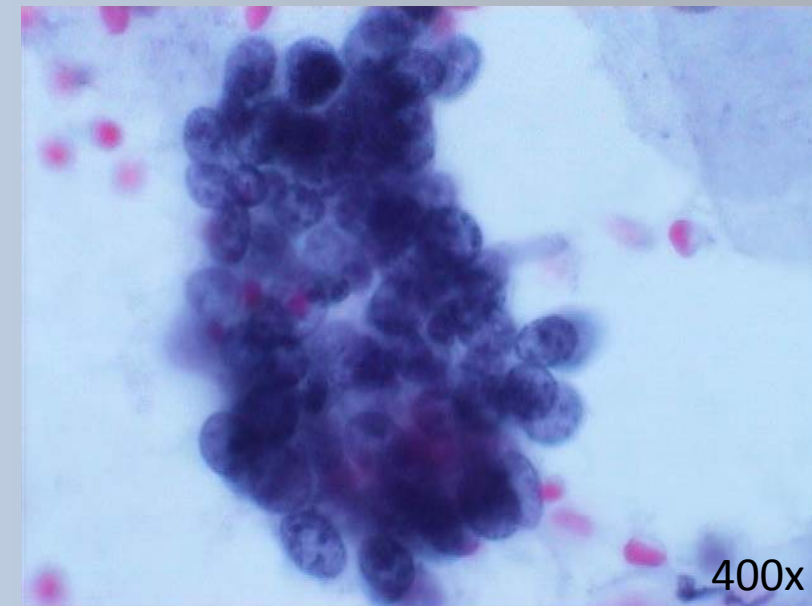
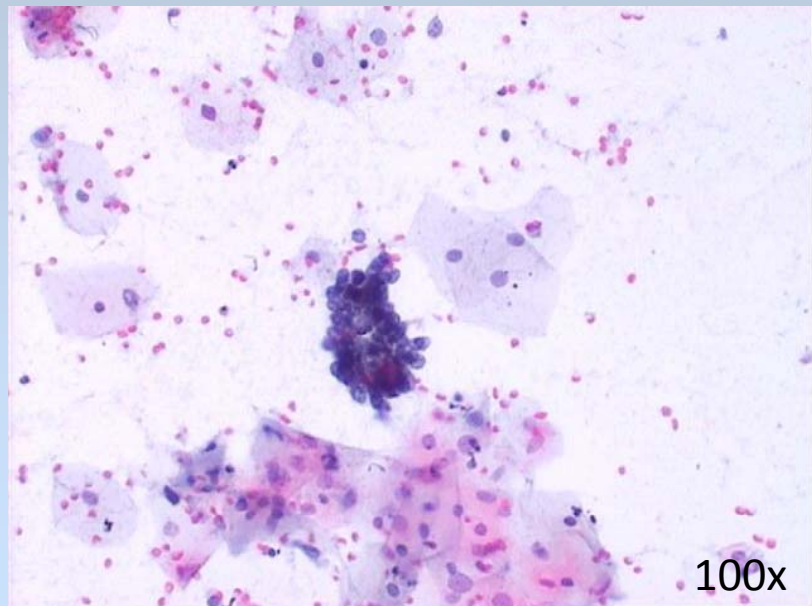
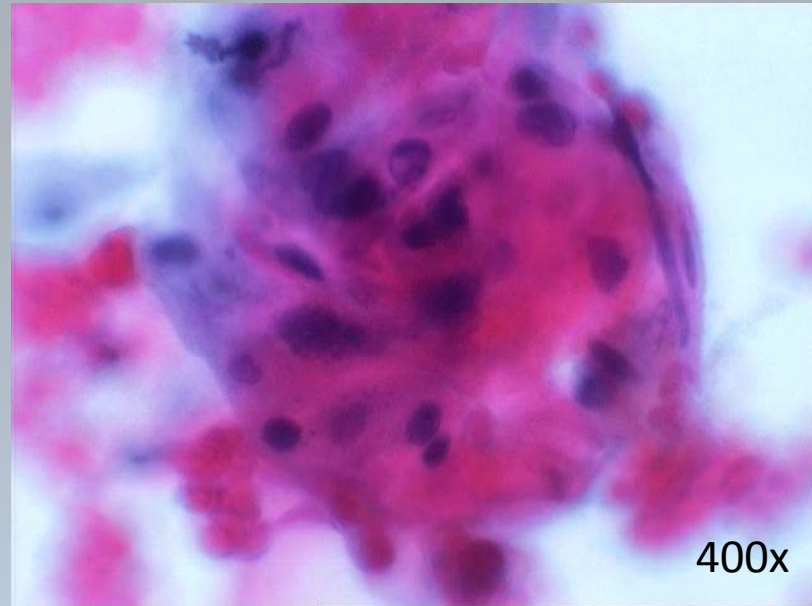
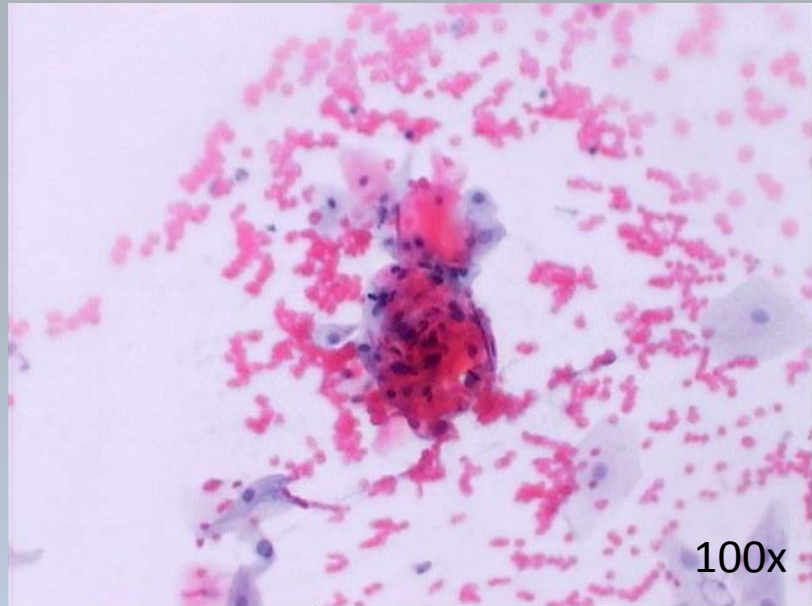
Case 2

Female, 84 years old

Reddish tumor 3 cm in diameter on labia minor, contact bleeding

Vulvar smear:



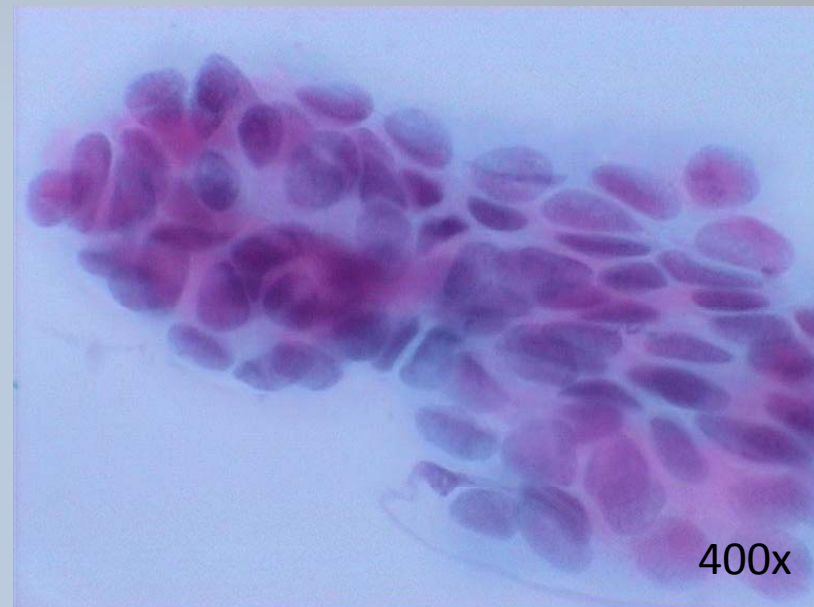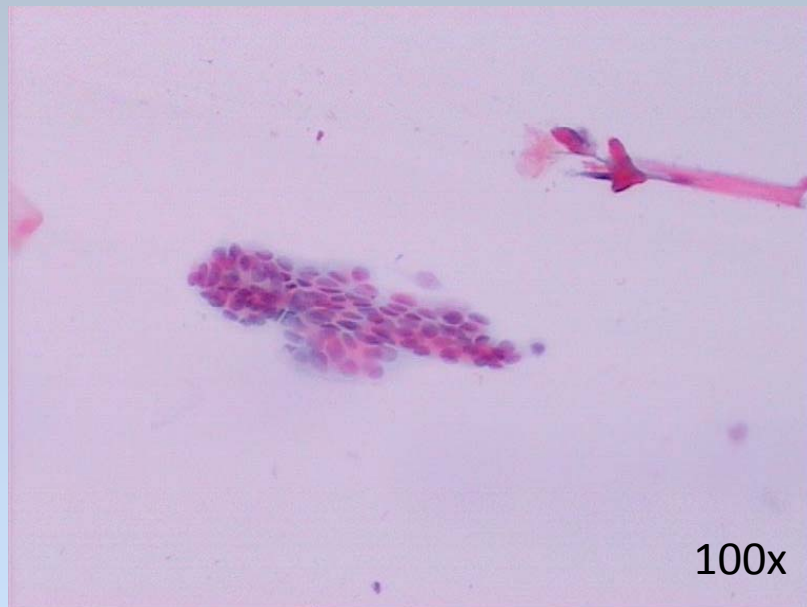


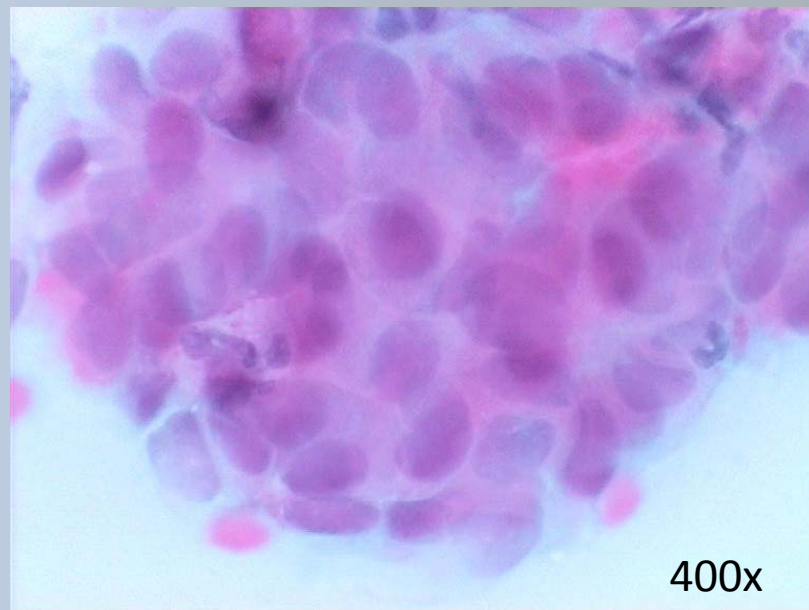
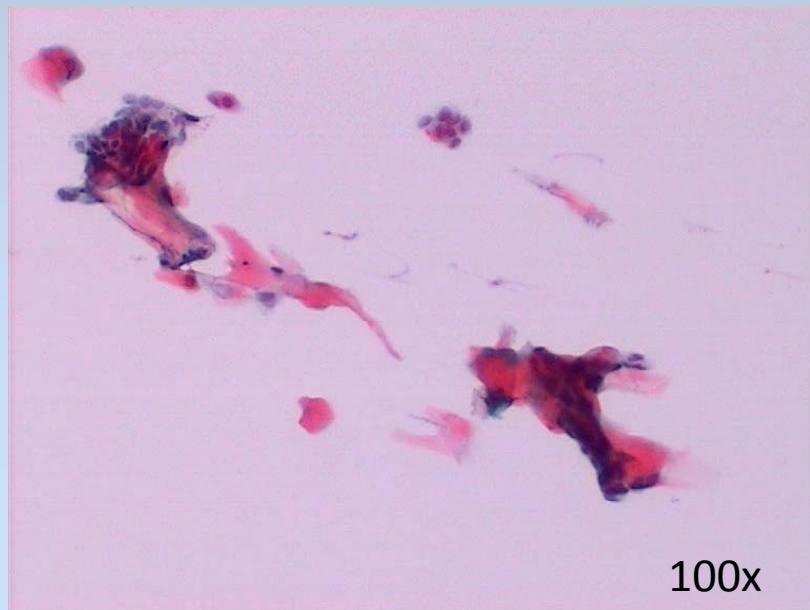
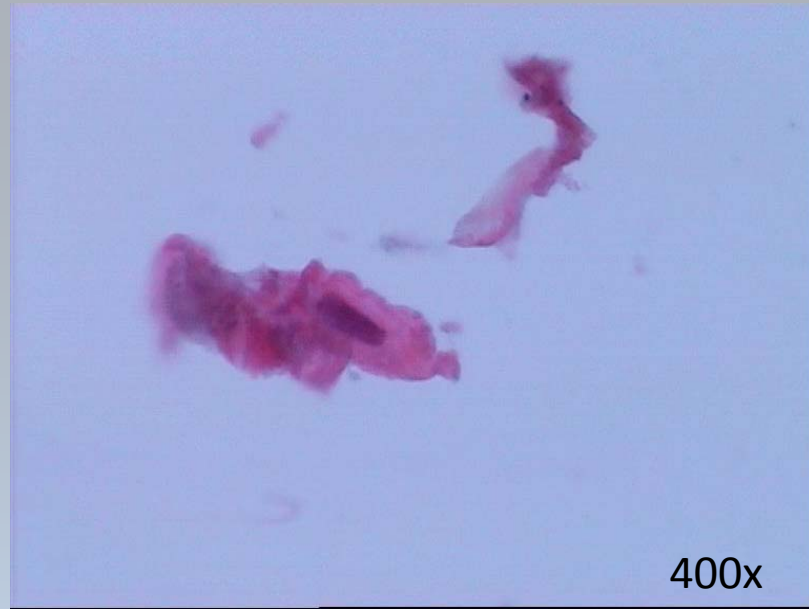
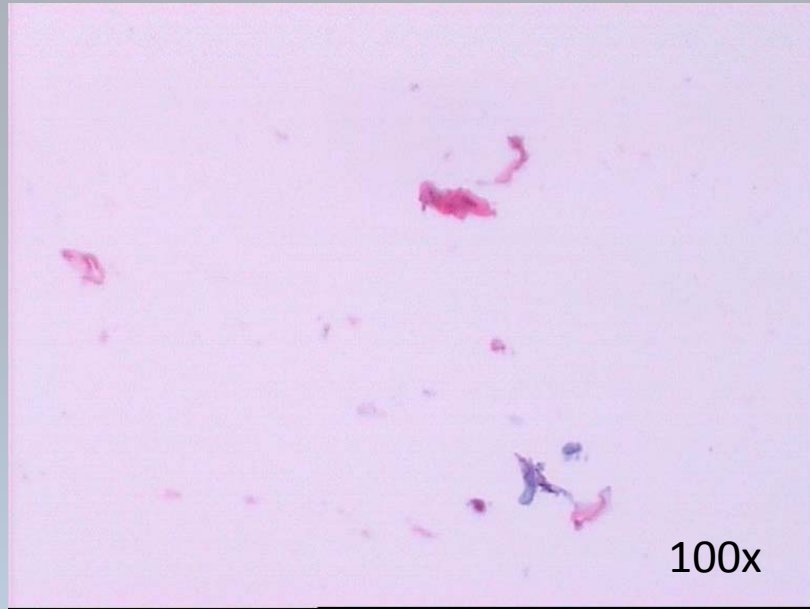
Case 3

Female, 60 years old

Two small white vulvar tumors 0,5 cm in diameter

Vulvar smear:





Case 4

Female, 87 years old

Tumor on labia maiora (left and right)

Vulvar smear:



